

# Good Occlusal Practice in Restorative Dentistry

**Hugh Devlin\***

Division of Dentistry, University of Manchester, Oxford Rd., Manchester. UK

Occlusion relates to the arrangement of the maxillary and mandibular teeth during chewing or at rest. While all dentists know of the importance of good marginal adaptation of their restoration to the health of the adjoining dental and periodontal tissues, some do not appreciate the potential consequences of poor occlusal contact to the opposing teeth and their supporting structures [1].

The masticatory (or stomatognathic) system is generally considered to be made up of the teeth, the periodontal tissues, and the articulatory system. Within the articulatory system, one can imagine the temporomandibular joints as the hinges, the masticatory muscles as the motors and the dental occlusion as the contacts. Dentists manage their patients' occlusion during routine restorative dental procedures because the occlusal surfaces of the teeth are usually involved in the provision of restorations [2]. But dentists should avoid unplanned occlusal change because it may lead to an iatrogenic problem or a restorative failure [3].

## Conforming to the Existing Occlusion

The principle of providing a new restoration that does not alter the patient's occlusion is described in restorative dentistry as the 'conformative approach' 4-5, and the vast majority of restorations are provided following this principle. The conformative approach is defined as the provision of restorations 'in harmony with the existing jaw relationships'.

If a dentist leaves a restoration in traumatic occlusion (in other words "high on the bite") then

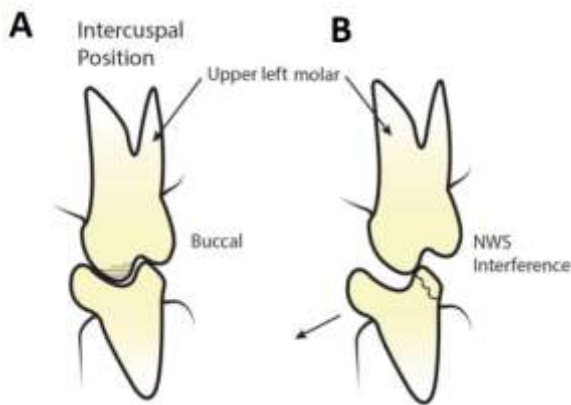
the patient may return with pain from that tooth, experience difficulty in eating and inability to place the teeth together as he was previously accustomed. The jaw musculature no longer functions harmoniously. One can conclude that restorations that conform to the existing intercuspal occlusion with simultaneous, harmonized contact of the teeth are therefore more likely to function satisfactorily.

Some patients may present with large, worn glass ionomer or fractured composite resin restorations. On examining the occlusion, the teeth may not appear to have separated as a result of the wear; rather, compensatory tooth eruption could have occurred so that the teeth appear ground into one another and have the appearance of a "pestle and mortar" (Figure 1A). In the example illustrated, the rim of the remaining tooth forms a non-working side (NWS) interference (Figure 1B) when the patient moves his jaw to the working side (patient's right side). This can put a damaging lateral load on the mandibular buccal cusp. Replacement of the occlusal restoration on the mandibular tooth should involve a slight reduction of the opposing palatal cusp so that the NWS interference is eliminated. So the crux of the conformative approach is that occlusal adjustment is possible in some teeth but one must not change the existing occlusal relationship of the other teeth.



Hugh Devlin is a Professor of Restorative Dentistry at the University of Manchester, UK. He joined as the teaching staff there in 1980 and remains a passionate teacher and researcher. He has 120 publications in refereed journals and is a registered specialist with the UK General Dental Council. Professor Hugh Devlin received the International Association of Dental Research Distinguished Scientist Award for research in prosthodontics and implants in 2011. He acts as the Associate Editor for both the Journal of Prosthodontics (2007- present) and Gerodontology journal (2012 - present). Professor Hugh Devlin recently published two textbooks "Review Questions for Dentistry" with Wiley-Blackwell (2015) and the "Oxford Handbook of Integrated Dental Biosciences" (2018). Professor Hugh Devlin has extensive experience of supervising postgraduate degrees (at PhD and MSc levels).

\*Correspondence: hugh.devlin@manchester.ac.uk



**Figure 1.** A worn restoration can introduce a non-working side interference resulting in the fracture of the tooth.

### The Reorganized Approach

The essence of the reorganized approach, as seen in most major restorative and all orthodontic treatment, is to change the occlusal relationship but still provide even simultaneous occlusal contacts as the mandible closes on its terminal hinge axis. The occlusal vertical dimension may change, but the teeth contact in the new intercuspal position (ICP) which coincides with the retruded contact position (RCP). During this closure movement there are no occlusal interferences resulting in damaging sliding movements. In planning the new occlusion, guidance in lateral excursions is best provided by the anterior teeth with an absence of non-working side interferences. The new occlusion should be visualized before tooth preparation using a wax-up on articulated models. In addition, the patient may need to wear an occlusal or stabilization splint<sup>3</sup> provided with the ideal occlusion to allow the condyles to assume their ideal position with no jaw muscle tension.

We may need to use the re-organized approach with multiple large restorations required in posterior quadrants. It is unavoidable, unless teeth can be prepared while still maintaining the existing occlusion. Many more complex cases are the result of tooth wear, where the restorations are re-establishing the original occlusal vertical dimension and in those cases the re-organized approach is used.

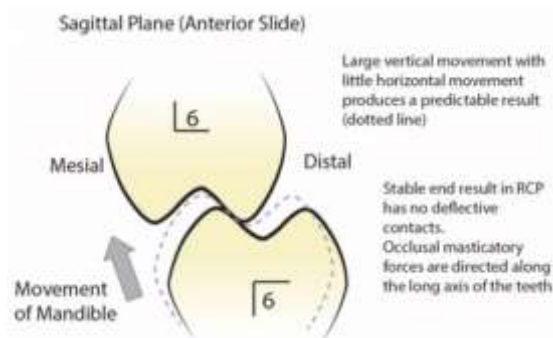
### Closing from the RCP to the ICP

If a patient is closing from the RCP to the ICP and there is a premature contact, this can result in forward displacement of the mandible. Not all such premature contacts result in symptoms. However, there are two locations where the teeth

can become traumatized; either at the initial point of contact of the teeth or at contact of the anterior teeth after the mandible has moved forward. With the latter, the anterior teeth can become mobile, and splayed out as they drift forward. If there is a small horizontal movement of the mandible after the initial contact has taken place, then occlusal adjustment is likely to succeed. Large horizontal mandibular movements are extremely difficult to correct.

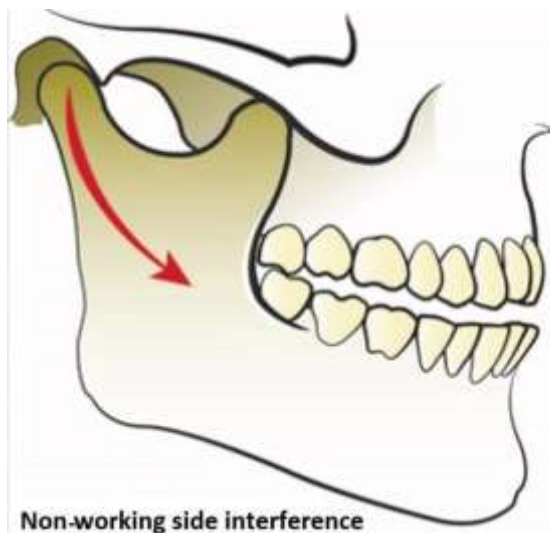
Planning the occlusal adjustment involves mounting the casts of the teeth in centric relation and carrying out an ordered sequence of adjustments that allows even tooth contact. Following the same sequence of adjustments in the patient's mouth should result in the new planned occlusion. Adjusting the cuspal inclines (Figure 2) will allow the teeth to come into even contact without the premature contact and forward slide of the mandible. Eliminating the posterior deflective contacts will allow the teeth to adopt a new stable occlusal position.

When a tooth with a premature contact is to receive a crown, it is important to remove the occlusal prematurity prior to preparing the tooth for the restoration. Without this preparatory adjustment, the new restoration may maintain or even accentuate the occlusal prematurity. Patients then may become aware of this premature occlusal contact and unable to adapt, complaining that their teeth no longer come together properly.



**Figure 2.** Occlusal adjustment by grinding the mesial facing inclines of the upper teeth or distal inclines of the lower teeth.

It is generally recommended that non-working side interferences are also removed on teeth that are about to be prepared for crown restorations. Let us assume we have detected a non-working side interference on an upper right first molar that is about to be prepared for a crown restoration (Figure 3).



**Figure 3.** Illustration of a non-working site interference.

This means that when the mandible moves to the left side (the working side), the mandibular teeth contact the occlusal interference on the upper right first molar. The smooth functioning of the masticatory musculature is disturbed as the mandible pivots about this tooth preventing the teeth on the working side from coming into

contact. Eliminating the interference involves reducing the cuspal incline on the upper molar over and above that required just for the crown preparation. If the non-working side interference is ignored, then the new crown restoration preserves the occlusal disharmony with potential crown fracture or temporomandibular disorders.

In summary, an occlusal examination and careful planning are essential steps in even the most minor of restorative treatments. For example, before replacing a small occlusal amalgam it is important to check the intercuspal position with articulating paper prior to tooth preparation. If possible, plan that the remaining tooth supports the occlusal load rather than the restoration.

### Conclusion

The textbook by Wassell [6] provides an excellent summary of the principles of occlusion. It is always easier to conform to the existing occlusion, but this may not be possible if extensive restorations are planned e.g. to restore gross toothwear. There are many textbooks (e.g. that by Wise [7]) that illustrate these principles for those seeking to learn the practical aspects of occlusal adjustment, conformational and reorganized techniques. Prior planning is essential.

### References

1. Davies, S., Gray, R. Occlusion: What is occlusion? *British Dental Journal*, 2001;191(5):235-45.
2. Davies, S., Gray, R., Smith, P. Occlusion: good occlusal practice in simple restorative dentistry. *British Dental Journal*, 2001;191(7):365-81.
3. Davies, S. Conformational, re-organized or unorganized? *Dental Update*, 2004;31(6):334-45.
4. Celenza, F.V., Litvak, H. Occlusal management in conformational dentistry. *The Journal of Prosthetic Dentistry*, 1976;36(2):164-70.
5. Wise, M.D. Occlusion and restorative dentistry for the general practitioner. *British Dental Journal*, 1982;152(12):407.
6. Wassell, R., Naru, A., Steele, J., Nohl, F. *Applied Occlusion*. Quintessence Publishing Company Limited, 2015. ISBN 185097277X, 9781850972778
7. Wise, M.D. *Failure in the restored dentition: management and treatment*. Quintessence Publishing Company, 1995. ISBN 1-85097-033-5.