

Evaluation of visual outcomes after toric intraocular lens implantation

Hui Ruan Ng, MBBS, Chon Han Goh, MBBS, You Siang Ngim, MOPthal, Juliana Jalaluddin, MOPthal

Ophthalmology Department, Hospital Pakar Sultanah Fatimah, Muar, Johor, Malaysia

ABSTRACT

Purpose: To evaluate postoperative visual acuity, refractive status and rotational stability of toric intraocular lens (IOL) in correcting pre-existing corneal astigmatism.

Methods: A total of 69 patients with topographic corneal astigmatism of 1.0 Diopter (D) and above who underwent cataract surgery between June 2015 and December 2016 were included in this retrospective observational study. All preoperative toric IOL calculations were performed using immersion biometry. Appropriate formula to calculate toric IOL power was applied (SRK/T, Holladay 1 or Hoffer Q formula). All patients undergone similar uncomplicated phacoemulsification with implantation of AcrySoft IQ SN6AT toric IOL of different powers. Visual outcome, refractive status and axis of lens were evaluated at six weeks postoperatively. Ethical approval from the Ministry of Health Medical Research Ethics Committee was obtained prior to commencement of study.

Results: The mean refractive astigmatism decreased from 1.69 D \pm 1.10 (SD) to 0.81 D \pm 0.40 (SD) at six weeks postoperatively. The mean postoperative spherical equivalent was at -0.37 D \pm 0.64 (SD). Mean LogMAR for uncorrected and corrected distance visual acuity in six weeks postoperative patients was at 0.29 \pm 0.16 (SD) and 0.12 \pm 0.12 (SD) respectively. Intraoperative to 6 weeks of postoperative comparison of IOL axis alignment showed low levels of rotation (mean 3.21 \pm 2.52 degrees).

Conclusion: Cataract surgery with implantation of toric IOL was stable and effective in improving pre-existing regular corneal astigmatism.

KEY WORDS:

Corneal astigmatism, cataract, toric intraocular lens

INTRODUCTION

Corneal astigmatism is part of refractive errors that can be addressed during a cataract surgery to achieve emmetropia. It has been estimated that 15-29% of patients with cataract have more than 1.5 D (Dioptres) of pre-existing astigmatism.¹ The introduction of toric IOL in correcting astigmatic and spherical errors has been in the market since 1994.²

There are various treatment modalities available to treat corneal astigmatism. Apart from correcting corneal

astigmatism with toric IOL implantation, procedures involving the manipulation of corneal curvature for example excimer laser refractive procedures and astigmatic keratotomies are other options available.³

As compared to incisional keratotomies, toric IOL implantations are able to minimize potential complications including globe perforation and exacerbation of dry eye symptoms.² Many studies have showed that toric IOL implantation in significant corneal astigmatism (more than 1.5 D) is an effective and predictable choice.⁴ Although toric IOL implantation has comparable clinical efficacy outcome with laser-in-situ-keratomileusis (LASIK), it provides a better postoperative improvement in corrected distance visual acuity (CDVA) and uncorrected distance visual acuity (UDVA).⁵ It is an effective alternative to LASIK when corneal laser surgical facilities are not conveniently available, or when the astigmatism is severe.⁶

However, postoperative rotation of toric IOL is a major concern in cataract surgery.^{4,7} Theoretical calculations showed that approximately one third of the astigmatism correction is lost if IOL is rotated 10 degrees off axis, two third of the effect is lost with 20 degrees of rotation and a net increase in astigmatism will result if the IOL is rotated more than 30 degrees.⁷ Therefore, a 10 degrees rotation is used as a limit before planning for IOL repositioning.

In this study, we are evaluating the visual outcomes and rotational stability of Acrysoft IQ SN6AT toric IOL for correcting the pre-existing corneal astigmatism in cataract patients among Malaysian population in a typical district hospital. The IOL models used were SN6AT3, SN6AT4, SN6AT5, SN6AT6, SN6AT7, SN6AT8 and SN6AT9.

MATERIALS AND METHODS

This is a retrospective observational study done in Hospital Pakar Sultanah Fatimah, Muar (HPSF) for patients undergoing cataract surgery with toric IOL implantation. Acrysoft IQ SN6AT toric IOL was used in this study. The surgeries were performed by three experienced surgeons in this hospital. All patients had undergone the surgery under local anaesthesia. Ethical approval for this study was obtained from the Medical Research and Ethics Committee Ministry of Health Malaysia on 26th May 2017 (NMRR ID: 17-834-34348).

This article was accepted: 23 October 2017

Corresponding Author: Hui Ruan Ng

Email: huiruan.ng@gmail.com

Table I: Visual acuity and refractive astigmatism before and after toric IOL implantation

Parameters	Preoperative	6 weeks Postoperative
	Mean \pm SD	Mean \pm SD
UDVA (logMAR)	0.80 \pm 0.23	0.29 \pm 0.16
CDVA (logMAR)	0.66 \pm 0.30	0.12 \pm 0.12
Refractive Astigmatism (D)	1.69 \pm 1.10	0.81 \pm 0.40

Table II: Mean residual astigmatism based on different IOL power

IOL Types (total n=55)	Mean Residual Astigmatism (D, Diopter)
SN6AT3 (n=18)	0.75
SN6AT4 (n= 13)	0.82
SN6AT5 (n=9)	0.80
SN6AT6 (n=10)	0.92
SN6AT7 (n=1)	0.75
SN6AT8 (n=3)	0.66
SN6AT9 (n=1)	1.25

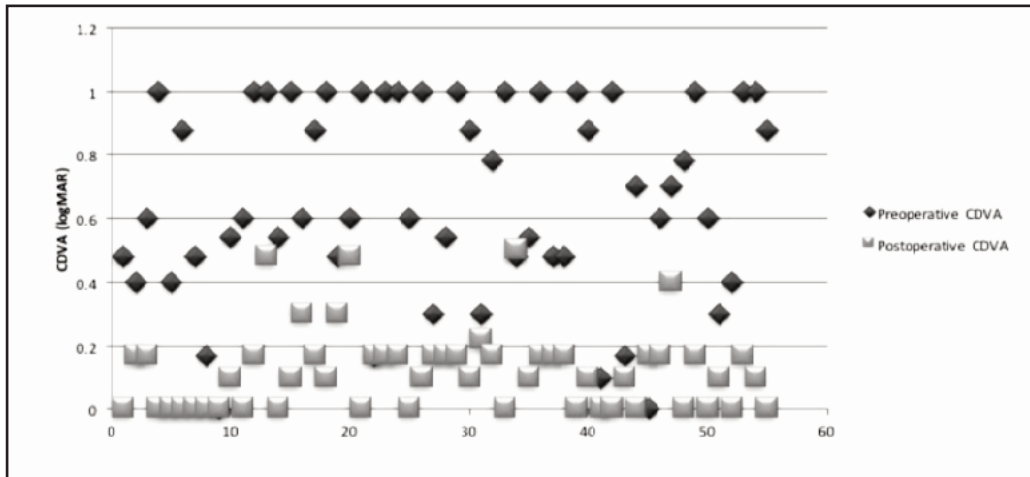


Fig. 1: Scatter plot showing distribution of preoperative and postoperative CDVA.

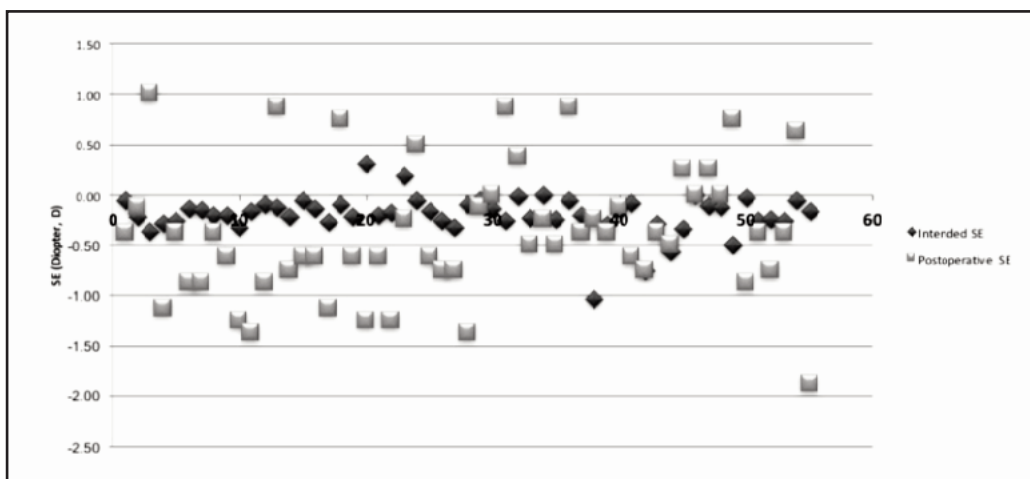


Fig. 2: Scatter plot showing distribution of intended and postoperative SE.

The inclusion criteria included patients with corneal astigmatism of 1.0 D or more who opted for toric IOL with no intra-operative complications. Patients who have undergone any form of previous ocular surgery, irregular cornea astigmatism, underlying retinopathy, maculopathy, optic neuropathy or history of ocular trauma were excluded from this study.

Data of patients who underwent cataract surgery with toric IOL between July 2015 and December 2016 were collected from National Cataract Surgery Registry and eye clinic cards. Patients that fulfilled the mentioned criteria were selected. Records gathered were documented into the data collection sheet and analysed using SPSS version 22.

Preoperatively, corneal astigmatism was established with an autokeratometer (NIDEK ARK-510A) whereas axial length was measured using immersion biometer (Echoscan NIDEK US-500). Visual acuities of patients were measured using Snellen chart, which were then converted into LogMAR units using online LogMAR-Snellen Conversion Calculator. Calculation of appropriate toric IOL cylinder power, axis placement of IOL and residual astigmatism was derived from an online programme available from the manufacturer (AcrySoft IQ Toric IOL Online Calculator).

Marking of the eye prior to toric IOL insertion was done in two stages; preoperative reference marking and intraoperative marking of the recommended axis of toric IOL placement. Reference point marking of the patient's eye was done with an axis marker at 3, 6 and 9 o'clock while patient is sitting up to prevent potential ocular cyclotorsion. An average cyclotorsion of the eyes are two to four degrees, however some patients may have up to 15 degrees of cyclotorsion.⁸ Subsequently, axis of recommended lens placement as determined by toric IOL calculator was marked at 2 points (180 degrees apart) with reference from the preoperative reference marking.

All patients underwent conventional phacoemulsification via a 2.75mm clear cornea incision and toric IOL inserted into the capsular bag. Toric IOL will then be rotated to align with the recommended axis point after removal of ophthalmic viscosurgical devices. All biometry readings were done by registered optometrists. The UDVA, BCVA, refractive astigmatism and corneal astigmatism was measured preoperatively and at six weeks postoperatively. Toric IOL position and rotation was recorded postoperatively.

RESULTS

A total of 69 cataract surgeries with toric IOL implantations were done during the study period. Sixty-one eyes from 48 patients fulfilled the criteria. However, there were six eyes which were lost to follow-up and therefore excluded from the study (n=55). The mean patient age at the time of surgery was 68.22 years, in a range of 31 to 86 years. The gender distribution was 31 (56.4%) males, 24 (43.6%) females. In terms of the laterality of intervened eyes, 30 were right eyes and 25 were left eyes.

Table I shows the mean values for preoperative and postoperative uncorrected distance visual acuity (UDVA),

corrected distance visual acuity (CDVA) and refractive astigmatism. There were significant differences between the preoperative and postoperative values ($p < 0.005$, Wilcoxon Signed Ranks Test). The residual refractive astigmatism was 0.81D (± 0.40). The mean reduction in refractive corneal astigmatism was 1.05, ± 0.85 D. Table II shows the mean residual astigmatism of each different toric IOL power from SNAT3 to SNAT9 (n refers to number of toric IOL used in each category)

In the postoperative group, 23 eyes (41.8%) achieve UDVA of logMAR 0.17 (Snellen chart 6/9) or better and 38 eyes (69.0%) achieve UDVA of logMAR 0.30 (Snellen chart 6/12) or better. In terms of postoperative CDVA, 50 eyes (90.9%) attain vision of logMAR 0.17 (Snellen chart 6/9) or better and 53 eyes (96.4%) attain vision of logMAR 0.30 (Snellen chart 6/12) or better (Figure 1).

The mean postoperative SE was -0.37 D (± 0.64 D); 40.0% of eyes operated were between ± 0.50 D and 85.4% were between ± 1.0 D (Figure 2). The mean toric IOL rotation was 3.21 degrees (± 2.52 degrees).

DISCUSSION

Based on the number of patients who had undergone cataract surgery at our centre during the study period, 28.1% had corneal astigmatism of 1.0 D or more. However, only 15.4% (69 eyes) of those with corneal astigmatism underwent toric IOL implantation due to financial constraint. Patients who underwent cataract surgery had to bear the cost of IOL themselves. Generally, patients who seek treatment at our centre (government-funded public hospital) comes from poor to middle socioeconomic background therefore, most of them opted for the monofocal IOL which is substantially cheaper.

Patients who underwent toric IOL implants at our centre had a significantly reduced refractive astigmatism after cataract surgery from mean of 1.69 D to 0.81 D. However, in comparison with other studies using the same toric IOL (Acrysoft IQ) postoperative refractive astigmatism was lesser at 0.67 D by Miyake et al., 0.37 D by Alba-Bueno et al and 0.32 D by Zarranz-Ventura et al.^{1,9,10} Based on our study, the lowest toric IOL cylinder power (SN6AT3) produced the least residual refractive astigmatism in comparison with its other counterparts. Our result is consistent with another study by Kramer et al which presented that toric IOL of low cylinder power (less than 2.5 D) had a significant lower residual refractive astigmatism.¹¹ This is because the same decentration, tilt or rotation of the toric IOL in lower cylinder power will give minor visual impacts in comparison with those of high cylinder power.¹

UDVA is an important parameter for surgeons to consider in modern cataract surgery which can be improved by implantation of toric IOL. In our study, 38 eyes (69.0%) achieved UDVA of 6/12 or better and 53 eyes (96.4%) attained a CDVA of 6/12 or better after cataract surgery. Miyake et al who used Acrysoft IQ toric IOL in their study achieved CDVA of 6/7.5 or better in 305 eyes (94.7%).⁹ Bachernegg et al studied implantation of the single-piece Bi-Flex T toric IOL and obtained a UDVA of 6/12 or better in 30 eyes (100%).⁴ Another study by Chang using single-piece

acrylic toric Staar TF/TL IOL obtained a CDVA of 6/12 or better in 92% of eyes.¹² Sun et al who used similar toric Staar TF in 130 eyes found 84% of eyes achieving CDVA of 6/12 or better.¹³

The mean toric IOL rotation in our analysis was 3.21 degrees (± 2.52 degrees) which was comparable with other studies. There were no toric IOL that had a misalignment of more than 10 degrees. Studies by Bauer et al, Farooqui et al and Zaranz-Ventura et al who used similar toric IOL models in this study showed mean toric IOL rotation of 2.5, 3.44 and 3.87 degrees respectively.^{3,5,10} In a meta-analysis review by Kessel et al, the general mean toric IOL rotation was less than 5 degrees.¹⁴ There are several factors leading to IOL misalignment. For example, incomplete removal of ophthalmic viscosurgical devices intraoperatively and insufficient extension of IOL haptics.⁹ Furthermore, the scale of the axis markers used preoperatively and intraoperatively are at 5 degree intervals causing slight IOL rotation inevitable.³ Observational errors can also happen when the slit lamp technique is used for axis measurement during postoperative follow-ups. Moreover, capsular bag shrinkage in the first three months postoperatively may cause IOL rotation.³ With each degree of misalignment, a 3.3% of astigmatism correction is reduced and with 30 degrees of misalignment, correction of astigmatism is lost.³ Therefore, accurate IOL placement and rotational stability are essential in preserving the outcome of astigmatism correction. In this study, there were no patients that required IOL repositioning.

One of the limitations that we faced in this study was the biometry assessment. In our centre, immersion technique was used to ascertain axial length and derive suitable IOL power. The setback of immersion technique is it is more operator-dependent as compared to the now gold standard optical biometry.^{2,15} Moreover, we do not have a designated optometrist for refractive assessment in this study. Besides that, only autokeratometer was used to measure corneal astigmatism in this study. The lack of corneal topography which is crucial to identify corneal irregularities was another limitation that we faced.

Lastly, it would be ideal if postoperative follow-up could be lengthened to more than six weeks. It is essential to repeat refractive assessment in certain patients because patients with poor refractive assessment at initial postoperative period may improve over time. Generally, patients were followed up between three and six months and up to two years in other studies.^{7,9,10,14}

In conclusion, the use of AcrySof IQ toric IOL is effective in correcting corneal astigmatism and provides good rotational stability. This study also proves that reasonably good outcome could be achieved to reduce corneal astigmatism even though advanced equipment such as optical biometry and corneal topography is still lacking in a typical district hospital setting in Malaysia.

ACKNOWLEDGEMENT

The authors would like to thank the Director General of Health Malaysia for his permission to publish this article.

REFERENCES

- Alba-Bueno F, González S, Biarnés M, Cabot J. Functional and refractive results after one month of AcrySof toric intraocular lens implantation. *J Optom* 2011; 4(2): 63-8.
- Visser N, Bauer NeJC, Nuijts RM. Toric intraocular lenses: historical overview, patient selection, IOL calculation, surgical techniques, clinical outcomes, and complications. *J Cataract Refract Surg* 2013; 39 (4): 624-37.
- Bauer NJC, deVries NE, Webers CAB, Hendrikse F, Nuijts RM. Astigmatism management in cataract surgery with the AcrySof toric intraocular lens. *J Cataract Refract Surg* 2008; 34(9): 1483-8.
- Bachernegg A, Ruckl T, Riha W, Grabner G, Dexl AK. Rotational stability and visual outcome after implantation of a new toric intraocular lens for the correction of corneal astigmatism during cataract surgery. *J Cataract Refract Surg*. 2013; 39(9): 1390-8.
- Farooqui JH, Koul A, Dutta R, Shroff NM. Management of moderate and severe corneal astigmatism with AcrySof toric intraocular lens implantation – Our experience. *Saudi J Ophthalmol*. 2015; 29(4): 264-9.
- Rosen ES. Chapter 5.8 Refractive Aspects of Cataract Surgery. In: Yanoff M, Duker JS. *Ophthalmology*. 4th ed. USA: Elsevier Saunders; 2014: 365-7.
- Zuberhuhler B, Signer T, Gale R, Haefliger E. Rotational stability of the AcrySof SA60TT toric intraocular lenses: A cohort study. *BMC Ophthalmol*. 2008; 8(8).
- Swami AU, Steinert RF, Osborne WE, White AA. Rotational malposition during laser in situ keratomileusis. *Am J Ophthalmol*. 2002; 133(4): 561-2.
- Miyake T, Kamiya K, Amano R, Iida Y, Tsunehiro S, Shimizu K. Long-term clinical outcomes of toric intraocular lens implantation in cataract cases with preexisting astigmatism. *J Cataract Refract Surg*. 2014; 40(10): 1654-60.
- Zaranz-Ventura J, Moreno-Montañés J, González-Jáuregui JC, Fernández-Yáñez EdN, Sádaba-Echarri LM. AcrySof® toric intraocular lens implantation in cataract surgery. *Arch Soc Esp Oftalmol*. 2010; 85(8): 274-7.
- Kramer BA, Berdahl JP, Hardten DR, Potvin R. Residual astigmatism after toric intraocular lens implantation: Analysis of data from an online toric intraocular lens back-calculator. *J Cataract Refract Surg*. 2016; 42(11): 1595-1601.
- Chang DF. Comparative rotational stability of single-piece open-loop acrylic and plate-haptic silicone toric intraocular lenses. *J Cataract Refract Surg*. 2008; 34(11): 1842-47.
- Sun XY, Vicary D, Montgomery P, Griffiths M. Toric intraocular lenses for correcting astigmatism in 130 eyes. *Ophthalmology*. 2000; 107(9): 1776-81.
- Kessel L, Andresen J, Tendal B, Erngaard D, Flesner P, Hjortdal J. Toric intraocular lenses in the correction of astigmatism during cataract surgery: A Systemic Review and Meta-analysis. *Ophthalmology*. 2016; 123(2): 275-86.
- Shah M SS, Shah K, Patel P. Biometry for IOL Power Calculation, Which Technology is Better Optical or Acoustic? *Sudanese Journal of Ophthalmology*. 2014; 6(1): 6-9.