

### Adult Intramuscular Shoulder Angiomyolipoma: A Rare Case

Kadhim Jawad Obaid, Yahya Mohammad Arpine, Nor Salmah Bakar, Marlina Tanty Ramli Hamid, Ahmed Ramzi Yusof

Faculty of Medicine, Universiti Teknologi MARA, Selangor, Malaysia

#### Received

3<sup>rd</sup> February 2016

#### Received in revised form

22<sup>nd</sup> October 2016

#### Accepted

26<sup>th</sup> October 2016

#### Corresponding author:

**Dr. Kadhim Jawad Obaid,**

Discipline of General Surgery,

Faculty of Medicine,

Universiti Teknologi MARA (UiTM),

Sungai Buloh Campus,

Sungai Buloh, Selangor,

Malaysia.

Tel: +6019-2216145

Email: kadhim@salam.uitm.edu.my

#### ABSTRACT

Intramuscular shoulder angiomyolipomas are very rare. We report a case in a 22-year-old male with a well circumscribed lesion located on the back of the shoulder. This lesion, differs from renal angiomyolipoma in terms of non-association with tuberous sclerosis, circumscription and male predominance. Another characteristic feature is the absence of epithelioid cells. Differential diagnosis includes lipoma, angioliipoma, angioleiomyoma, hemangioma, myoliipoma and liposarcoma. It is distinguished from the above mentioned entities by the presence of a combination of thick-walled blood vessels, smooth muscle and fat.

**KEYWORDS:** Intramuscular, angiomyolipoma, shoulder

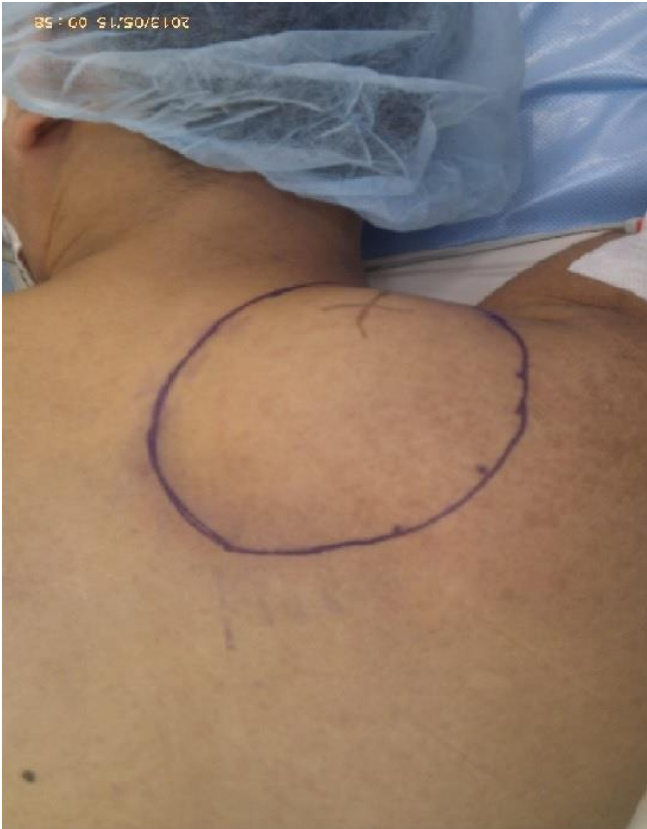#### INTRODUCTION

Angiomyolipomas are uncommon lesions that are seen most often in the kidney but have also been described at many other sites including skin, liver, spleen, lymph node, spermatic cord, penis, vagina, uterus, oral cavity, nasal cavity, lung, heart, colon, abdominal wall, retroperitoneum, mediastinum, epidurally in the spine and subgalea aponeurotica [1]. Angiomyolipomas belong to the family of perivascular epithelioid cell tumors and are characteristically positive for HMB-45 [2]. Intramuscular angiomyolipoma is a very rare benign vascular tumor and has only been reported in children [3]. Intramuscular angiomyolipoma consist of convoluted thick-walled blood vessels, adipose tissue and smooth muscle bundles. It differs from renal

angiomyolipoma in terms of clinical association, circumscription and HMB-45 immunoreactivity.

#### CASE PRESENTATION

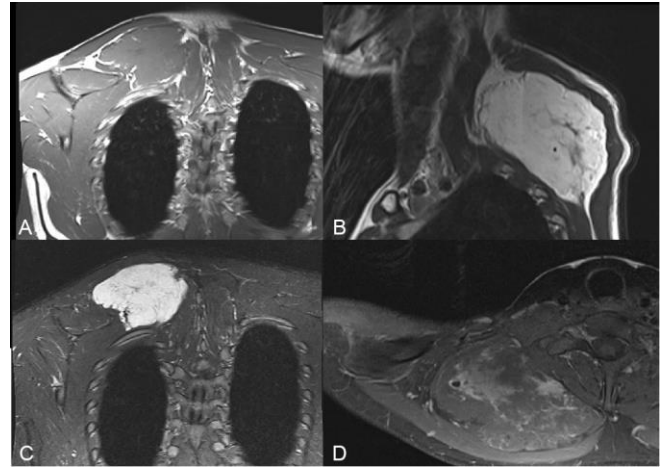
A 22-year-old male presented with a 9-year history of a painless lump on the back of the right shoulder slowly increasing in size with time. On examination, the mass is soft, non-tender, well-localised, measuring 10 cm × 7 cm in size, with no local increase in temperature. The skin overlying the mass was normal and pinchable (Figure 1). The mass became less obvious and less palpable with elevation of the right shoulder (contraction of the trapezius muscle) suggesting the location of the mass underneath the muscle. The patient had no signs of tuberous sclerosis.



**Figure 1** Pre-operative picture of the patient showing the lump on the back of the right shoulder

Contrast-enhanced magnetic resonance imaging (MRI) revealed a large well-defined, lobulated mass measuring approximately 9.5 cm (w) × 5.6 cm (ap) × 5.9 cm (h) seen deep to right trapezius muscle likely arising from the rhomboid muscle. The mass was vascularised, isointense to muscle on T1W, hyperintense on T2W and demonstrated areas of patchy enhancement post-gadolinium. No septation or cystic changes within. There was mass effect on the right erector spinae muscle from the lower cervical to the upper thoracic level. No extension into the thoracic cavity or marrow changes in the underlying ribs noted (Figure 2).

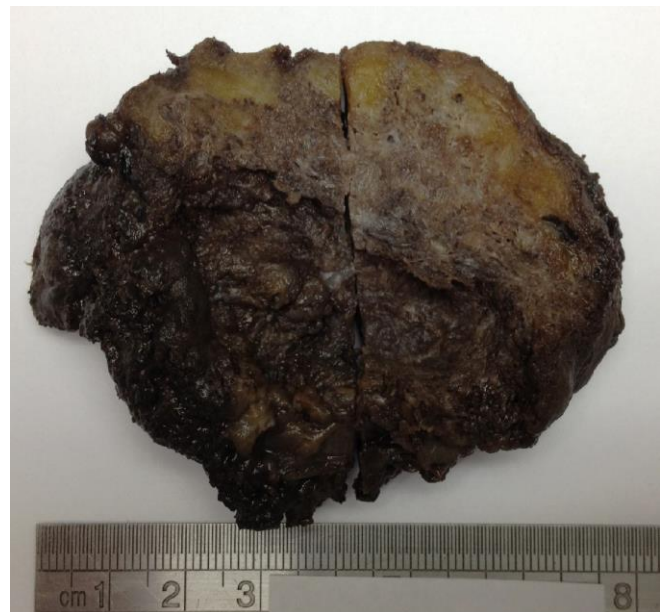The mass was completely excised via a transverse incision in the back of the shoulder through the skin and subcutaneous tissue, separation of the middle fibers of the trapezius muscle. The mass was very soft and vascular with abundance of surrounding blood vessels. The mass sent for histopathologic evaluation.



**Figure 2** MRI images of the tumour. A) T1 coronal image showing the mass returns isointense signal to muscle. B) T2 sagittal image showing hyperintense signal to muscle. C) The mass is not suppressed in STIR sequence. D) Axial post contrast image show heterogenous enhancement. Note a signal void focus within the tumour in keeping with calcification.

### Pathological Findings

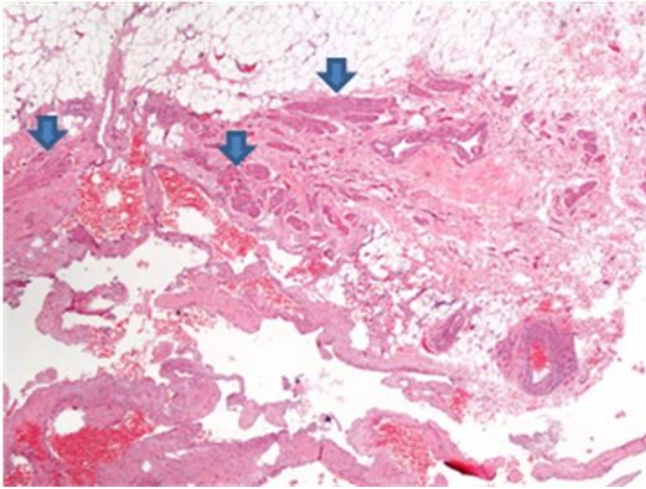
Macroscopic examination revealed a piece of dark brown ovoid firm mass measuring 80 mm × 45 mm × 22 mm. The mass has glistening yellow cut surface at the periphery. The rest of the areas appear spongy and brownish in colour.



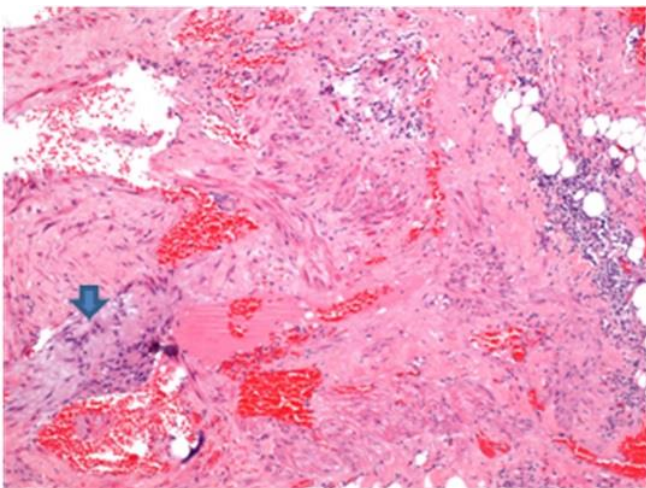
**Figure 3** Predominantly fat component at the edge of the mass (top) and sponge-like appearance of the richly vascular area (lower half)

Microscopic examination revealed a circumscribed lesion consisting of intersecting vascular spaces together with bundle of smooth muscle and mature adipose tissue, consistent with an

angiomyolipoma. A few vessels show organized thrombus.



**Figure 4** The mass is composed of mature adipose tissue (top), smooth muscle bundles (arrow) and vascular channels (bottom). (H&E magnification  $\times 4$ )



**Figure 5** There is little perivascular epithelioid cells present in this specimen (arrow). These cells are negative with HMB-45 marker by immunohistochemical stain. (H&E magnification  $\times 10$ )

## DISCUSSION

Angiomyolipoma is probably a hamartomatous process which is seen mainly in the kidney. It is often seen in patients with tuberous sclerosis. It shows a female predominance and is composed of an admixture of small to medium-sized thick-walled blood vessels, smooth muscle cells and adipose tissue. A population of epithelioid or clear cells may also be seen, arranged around the blood vessels [1]. Angiomyolipomas are rarely seen at many other locations including skin, liver, spleen, lymph node, spermatic cord, penis, vagina, uterus, oral cavity, nasal cavity, lung, heart, colon,

abdominal wall, retroperitoneum, mediastinum, epidurally in the spine, and subgalea aponeurotica [1]. Intramuscular angiomyolipomas are rare and only reported in children [3]. In our case, it differs from renal angiomyolipomas in that the patient is male, without any association with tuberous sclerosis and are HMB-45 negative. Histologically, they are composed of thick-walled blood vessels, smooth muscle cells and mature fat in variable proportions. Epithelioid cell component is usually absent in intramuscular angiomyolipomas, in contrast to renal angiomyolipomas, which may be responsible for HMB-45 negativity of the former tumor [1].

Histologic differential diagnosis of intramuscular angiomyolipoma include lipoma, angioliipoma, angioleiomyoma, hemangioma with partial involution and fatty replacement, and myoliipoma [3]. Smooth muscle bundles are not seen in angioliipoma, whereas angioleiomyoma lacks an adipose tissue component. Hemangiomas do not show a smooth muscle component. Angiomyolipoma is differentiated from myoliipoma by the absence of thick-walled blood vessels in the latter. Intramuscular angiomyolipomas are rare and to the best of our knowledge, no case have been published to date. Our findings in this case correlate with other cases in terms of male predominance, lack of association with tuberous sclerosis and solitary nature of the tumor.

Cutaneous angiomyolipomas reported in a series in terms of location [4]. All cutaneous angiomyolipomas presented in the reported series were acral in location. Intramuscular angiomyolipoma is uncommon and should be considered in the differential diagnosis of any subcutaneous tumor with a combination of blood vessels, smooth muscle cells and adipose tissue.

## Conflict of Interest

Authors declare none.

## Acknowledgements

A special thanks to Dr. Mohd Shukry Bin Mohd Khalid (Radiology), Dr. Khariah Binti Mat Nor (Radiology), Dr. RA Adnan (Pathology) for their help and support.

**REFERENCES**

1. Val-Bernal JF, Mira C. Cutaneous angiomyolipoma. *J Cutan Pathol.* 1996; 23:364-8.
2. Ma L, Kowalski D, Javed K, Hui P. Atypical angiomyolipoma of kidney in a patient with tuberous sclerosis: A case report with p53 gene mutation analysis. *Arch Pathol Lab Med.* 2005; 129:676-9.
3. Krzeszewski M, Godziński J, Jeleń M, Sulka W, Klempous R, Borecki P, Klempous J. Intramuscular angiomyolipoma in children own observations. *Med Wieku Rozwoj.* 2004; 8(4 Pt 2):1105-12.
4. Fitzpatrick JE, Mellete JR Jr, Hwang RJ, Golitz LE, Zaim MT, Clemons D. Cutaneous angiolipoleiomyoma. *J Am Acad Dermatol.* 1990; 23:1093-8.