

Capitate Metastases in Adenocarcinoma Lung: A Rare Occurrence

Jaspreet KAUR¹, Renu MADAN¹, Maneesh Kumar VIJAY²,
Pramod Kumar JULKA¹, Goura Kishore RATH¹

Submitted: 21 Jul 2014
Accepted: 19 Nov 2014

¹ Department of Radiation Oncology, DR BRA Institute Rotary Cancer Hospital, All India Institute of Medical Sciences, New Delhi 110029, India

² Department of Pathology, All India Institute of Medical Sciences, New Delhi 110029, India

Abstract

Metastatic carcinoma is the most common malignancy of the bone. Metastases to the upper limbs of the skeleton are extremely uncommon, with only 10–15% occurring in this region. Metastases to the hand and wrist comprise about 0.15% of all hand tumours, and only 0.1% of all metastases. Carpal bone metastases are much rarer than those to the metacarpal and phalangeal bones. They usually masquerade as more common hand pathology such as arthritis or osteomyelitis. Given the bleak prognosis of carpal metastatic disease in lung cancer, treatment of a metastasis to the hand is usually palliative. Contrary to earlier beliefs, palliative radiotherapy plays a significant role in pain relief and improving hand mobility in patients diagnosed with metastatic disease of the hand. We report a case of adenocarcinoma of the lung with metastases to the capitate bone of the carpus treated with palliative radiotherapy.

Keywords: carpal bone, metastases, lung cancer, palliative, radiotherapy

Introduction

Metastatic carcinoma is the most common malignancy of the bone. The skeleton is the third most common site of metastases after the lungs and the liver, with more than 50% of cancers spreading to the bones. Common malignancies that metastasize to bones involve the lung, breast, prostate, and kidney. The sites most frequently involved are the spine, pelvis, ribs, skull, and proximal long bones. Metastases to the upper limbs of the skeleton are extremely uncommon with 10–15% occurring in this region. Metastases to the hand and wrist comprise about 0.15% of all hand tumours, and only 0.1% of all metastases (1). The true incidence may be much higher due to a lack of reporting, or subclinical cases or missed cases in severely debilitated patients (2). Metastases to the carpal bones are much rarer than those to the metacarpal and phalangeal bones. A high index of suspicion has to be maintained to detect these lesions as they often resemble other common hand ailments. We report a case of lung cancer with metastases to the capitate bone of the carpus that was treated with palliative radiotherapy.

Case Report

A 52-year-old male presented with fever, left-sided chest pain and pain in the right wrist for two months. There was no history of trauma to the right hand. The patient was a chronic tobacco chewer and beedi smoker (beedi is a hand-rolled cigarette used in South Asia made of unprocessed tobacco wrapped in leaves) for the last 15 years. He had quit smoking 15 days prior to reporting to the hospital. Physical examination of the hand revealed severe tenderness and swelling at the right wrist joint along with clubbing of the nails. Movements at the wrist joint were restricted. There was no neurovascular deficit. Chest examination revealed decreased air entry in the left side on auscultation. Plain radiograph of the chest showed left upper lobe and middle lobe opacity. Contrast enhanced computed tomography of the chest showed a 7.1 x 6.1 cm heterogeneous mass lesion, predominantly necrotic, with amorphous calcification in the left infrahilar region, with encasement of the left bronchus intermedius. Ultrasound-guided trucut biopsy from the lung mass revealed a histopathological diagnosis of adenocarcinoma that showed thyroid transcription factor-1(TTF-1)

positivity. It was negative for epidermal growth factor receptor (EGFR) mutation (Figure 1). A total body bone scan with Technitium-99 revealed an increased uptake in the capitate bone of the right wrist (Figure 2) and the head of right femur. Radiograph of the right wrist showed an osteolytic lesion in the capitate of the right wrist (Figure 3). The case was discussed in a multidisciplinary clinic and it was decided to treat the patient with palliative radiotherapy to the wrist. Radiotherapy simulation was done on a fluoro-simulation and a dose of 8 Gy in single fraction was delivered with 6 Mega Voltage(MV) X-rays on a linear accelerator. Two weeks after radiotherapy, the patient was started on palliative chemotherapy with Paclitaxel (200mg/m²) and Carboplatin (AUC-6) along with Injection Zoledronic acid to be taken every three weeks. The patient has received three cycles of chemotherapy to date. There was significant improvement in pain relief and mobility around the wrist joint four weeks after completion of radiotherapy.

Discussion

Primary carpal bone tumours are quite rare. Bronchial carcinoma is the principal contributor to metastases to bones of the hand. There is no robust data pertaining to the percentage of lung cancers that metastasize to hand bones; however, approximately 50% of the cases reported in the literature are from a primary tumour in the lung (3). Similarly, there is little information as to which type of lung cancer is more prone to metastasize to the hand or the carpal bones due to the paucity of cases. Metastases to the carpal

bones are much rarer than those to the metacarpal and phalangeal bones. The incidence of metastasis to the metacarpals is 17%; phalanges, 66%; and carpal bones, 17% out of all acrometastases to hand bones (4). Fewer than 20 case reports are available in the literature that deal with metastases to the carpal bones (5). Hand metastasis is often a late manifestation of disseminated disease or it can be a primary presentation of an occult cancer. Therefore, its presence often denotes a poor prognosis.

There are only two reports of metastatic disease in the capitate bone of the wrist. The first case is that of a clear cell sarcoma of the right foot that metastasized to the capitate bone, reported by Reichert et al. (6). The second case is a malignant melanoma in the inter-scapular region that metastasized to the capitate bone of the wrist (7). To our knowledge, the index case will be the third case of metastatic disease in the capitate.

A differential diagnosis of pain and swelling of the wrist joint in this patient consisted of hypertrophic osteoarthropathy, gouty arthritis, rheumatoid arthritis, osteoarthritis, tendon sprain, metabolic bone disease, soft tissue tumours, and bone tumours (benign or malignant). Hypertrophic osteoarthropathy (HOA) is characterised by polyarthritis, clubbing of the fingers and toes and periosteal proliferation of long bones. It was excluded in the index case due to the solitary nature and location of the lesion. Metastatic lesions of the hand often present with pain, redness, swelling, and loss of function mimicking some benign inflammatory pathology like arthritis or osteomyelitis or some other infection of the hand. Rarely can

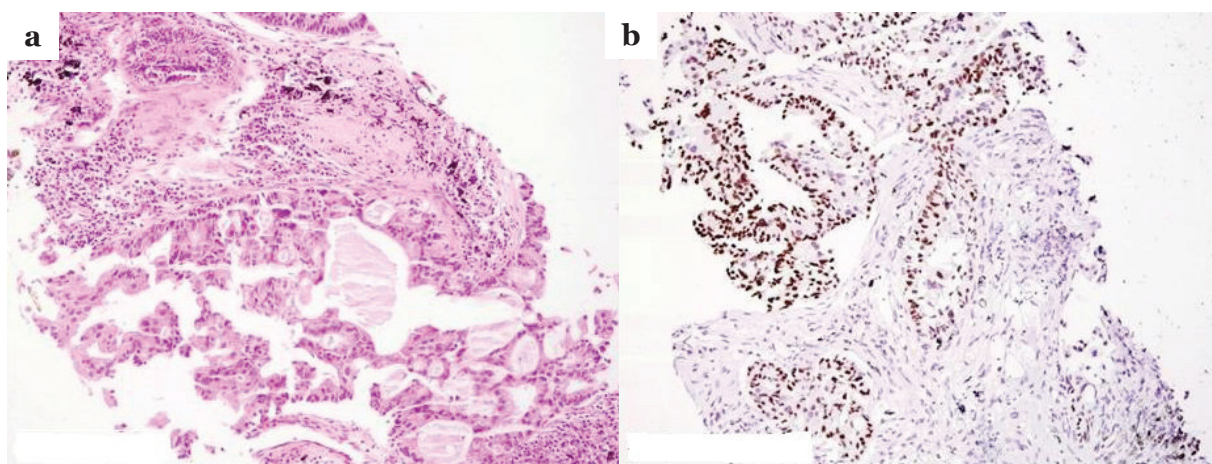


Figure 1: Section (a) showing a malignant tumor arranged in glandular pattern and infiltrating the lung parenchyma. The tumor cells are immunopositive for TTF-1 (b), confirming its pulmonary origin (hematoxylin and eosin stain, 100× magnification).

they manifest as an ulceration of soft tissue. The lesions are practically always lateralised with bilateral involvement being extremely rare. The radiographic appearance of the lesion depends on the location of the primary. Breast and lung cancers commonly cause lytic lesions, whereas lesions caused by thyroid and prostate cancers often have an osteoblastic appearance. Radiographic appearance in the index case was uniformly lytic. TTF-1 positivity in the biopsy specimen is a reliable immunohistochemical marker for adenocarcinoma lung and the absence of EGFR mutation denotes that this patient cannot be given tyrosine kinase inhibitor therapy like gefitinib or erlotinib. These factors do not play any role in metastases to small bones. Although the index case did not have a biopsy result that proved malignant, the clinical and radiologic features in the presence of lung cancer pointed to the diagnosis of metastases in the capitate bone of the wrist.

The mechanism by which cancer cells spread to the hand remains obscure. A variety of factors including trauma, tissue thermal differences, hormonal influence, hemodynamics, and host immune responses have all been implicated (8).

Hematogenous dissemination of tumour emboli is the presumed mechanism in most of the cases. Malignant cells of the lungs have been shown to have unimpeded access to the distal arterial system. This explains a much higher incidence of hand metastases in lung cancers compared to other malignancies (9). Since these lesions usually occur in the dominant hand, another proposed explanation is that there is a higher blood flow and greater exposure to trauma, resulting in decreased resistance of the surrounding tissue, and the growth and settlement of tumour emboli. Our case also had a lesion in the dominant hand.

The mean duration of survival in patients with acrometastases is six months. Given the bleak prognosis of carpal metastatic disease in lung cancer, treatment of a metastasis to the hand is usually palliative and may involve amputation, simple excision or wide excision of the tumour in conjunction with other therapeutic modalities. Local radiotherapy often gives pain relief with good functional outcome and organ preservation. A recent report by Flynn et al. highlighted the role of palliative radiotherapy in pain relief and in improving hand mobility in patients diagnosed with metastatic disease to the hand. The dose

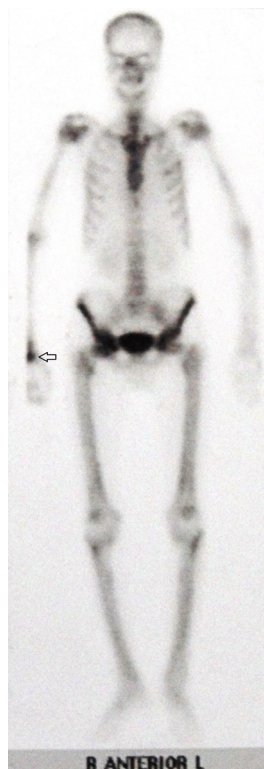

Figure 2: Bone Scan with Technetium 99m demonstrating uptake in in right wrist and head of right femur.

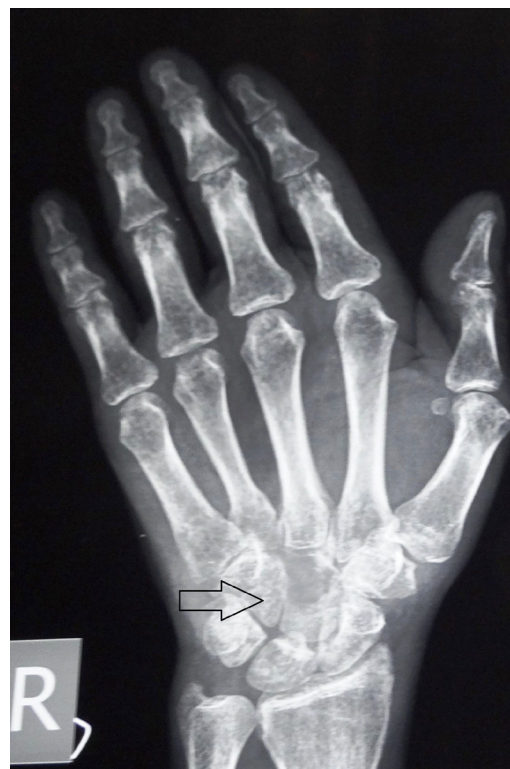

Figure 3: Radiograph of the right hand revealing a lytic lesion in capitate bone.

of palliative radiotherapy prescribed was 8Gy in single fraction which is similar to that in the present case (10). Radiotherapy served to relieve pain and to permit the patients to regain complete use of their hand. Thus, radiotherapy is an effective and noninvasive treatment that improves a patient's quality of life.

To conclude, the appearance of metastatic disease in carpal bones is rare. Pain and swelling are the most common symptoms, often mistaken for benign inflammatory conditions. Careful evaluation of such lesions is important for timely initiation of treatment to relieve the symptoms even if histological diagnosis from the secondary is not available. Although the presence of carpal metastases foreshadows a poor prognosis, palliative radiotherapy in such cases can provide significant pain relief and better organ function.

Acknowledgement

None.

Conflict of Interest

None.

Funds

None.

Authors' Contributions

Conception and design, drafting of the article: JK, RM

Critical revision of the article for the important intellectual content, final approval of the article: JK, PKJ, GKR

Provision of study materials or patient, administrative, technical or logistic support: MKV

Correspondence

Dr Jaspreet Kaur
MD (AIIMS, New Delhi)
Department of Radiation Oncology
DR BRA Institute Rotary cancer Hospital
All India Institute of Medical Sciences
New Delhi, 110029
India.
Tel: +91-9810966061
Email: drjaspreet.ro@gmail.com

References

1. Kerin R. The hand in metastatic disease. *J Hand Surg Am.* 1987;**12(1)**:77–83.
2. Hayden RJ, Sullivan LG, Jebson PJ. The hand in metastatic disease and acral manifestations of paraneoplastic syndromes. *Hand Clin.* 2004;**20(3)**:335–343.
3. Kumar PP, Kovi J. Metastases to bones of the hands and feet. *J Natl Med Assoc.* 1978;**70(11)**:837–840.
4. Basora J, Ferry A. Metastatic malignancy of the hand. *Clin Orthop Relat Res.* 1975;**108**:182–186.
5. Rinonapoli G, Caraffa A, Antenucci R. Lung cancer presenting as a metastasis to the carpal bones: a case report. *J Med Case Rep.* 2012;**6(1)**:384. doi: 10.1186/1752-1947-6-384.
6. Reichert B, Hoch J, Plotz W, Mailander P, Moubayed P. Metastatic clear-cell sarcoma of the capitate. A case report. *J Bone Joint Surg Am A* 2001;**83A(11)**:1713–1717.
7. Tomas X, Conill C, Combalia A, Pomes J, Castel T, Nicolau C. Malignant melanoma with metastasis into the capitate. *Eur J Radiol.* 2005;**56(3)**:362–364.
8. Long LS, Brickner L, Helfend L, Wong T, Kubota D. Lung cancer presenting as acrometastasis to the finger: a case report. *Case Rep Med.* 2010; **2010**:234289. doi: 10.1155/2010/234289.
9. G. Asencio, CH. Hafdi, H. Pujol, and Y. Allieu. Osseous metastases in the hand. A general review of three cases. *Ann Chir Main.* 1982;**1(2)**:137–145.
10. Flynn CJ, Danjoux C, Wong J, Christakis M, Rubenstein J, Yee A, et al. Two cases of acrometastasis to the hands and review of the literature. *Curr Oncol.* 2008;**15(5)**:51–58.