

# Transorbital Sonographic Measurement of Normal Optic Sheath Nerve Diameter in Nigerian Adult Population

Ismail ANAS

Submitted: 6 Mar 2014

Accepted: 22 Jun 2014

*Department of Radiology, Bayero University/Aminu Kano Teaching Hospital, PMB 3011, Kano, Nigeria*

## Abstract

**Background:** The optic nerve covering is elastic enough to allow a detectable enlargement in response to changes in intracranial pressure. The objective of the present study was to determine the optic nerve sheath diameter (ONSD) in normal Nigerian adults.

**Methods:** This study was conducted on 400 healthy adults. The ONSD was measured at 3 mm posterior to the globe using a 7.5 MHz linear transducer.

**Results:** The study population consisted of 192 males and 208 females with mean age of 36.94 years (SD 16.63). The range of values for ONSD was 3.36 to 5.1 mm. The median right ONSD was 4.110 with a range of 3.36–4.86 mm (mean: 4.18 mm (SD 0.49)), while the median left ONSD was 4.35 mm with a range of 3.77–5.10 mm (mean: 4.17 + mm (SD 0.44)). No statistically significant variation in ONSD was found between the right and left sides ( $P = 0.12$ ) and also between male and female participants ( $P = 0.296$  and  $0.745$  for the respective right and left ONSD).

**Conclusions:** The normal reference values of ONSD measurements in adults were obtained. It showed no significant correlation with side (right and left), age, and sex. Furthermore, there is no significant correlation of ONSD with the body height and weight.

**Keywords:** optic nerve, diameter, sonography, intracranial pressure

## Introduction

The optic nerve, also known as second cranial nerve (CNII), originates from embryonic retinal ganglion cell. The function of optic nerve is to carry the electrical impulses from retina to brain, thus, it can also be termed as the nerve of vision. It is myelinated and has three meningeal layers covering its subarachnoid space continuous with that of the brain (1–3). Hence, the intra-orbital subarachnoid space surrounding the optic nerve is responsive to the same pressure changes as the intracranial compartment. This makes the human optic nerve sheath elastic enough to allow a detectable dilatation in response to increased intracranial pressure (ICP) (1,4,5). Therefore, raised cerebrospinal fluid (CSF) pressure is transmitted along this space and may compress the venous drainage of the eye to produce papilloedema (swelling of the optic disc), which is detectable at funduscopy (2). Indeed, papilloedema is an indirect and late indicator of raised ICP, whereas a pressure rise in optic nerve sheath (and the resulting enlargement of the optic nerve diameter) is a more dynamic process (4).

The retrobulbar optic nerve sheath diameter (ONSD) can be measured at a position 3 mm

posterior to the globe, where ultrasound contrast is greatest with more reproducible results, and anatomically, the anterior aspect of the nerve is most distensible (6,7). In a recent study, Newman et al. (6) found the average ONSD in the control group as 3.6 mm compared to 4.6 mm in the group with raised ICP. The authors also noted that the absence of papilloedema in the acute situation; however, the increased ONSD may act as a marker for raised ICP before the development of papilloedema. The measurement of ONSD is an easily learned, reproducible technique with low intra-observer and inter-observer variation, if one takes the measurement at 3 mm posterior to the posterior scleral surface of the globe. In this context, Ballantyne et al. (8) reported an average inter-observer variation of + 0.2 mm, which is comparable to the inherent variability of the ultrasound machine. Moreover, the cystic nature of the eye and its superficial location along with the use of high frequency transducers in ultrasound machine make it possible to clearly visualise normal anatomy and pathologic conditions. In the cases with raised ICP, sonography is a useful follow-up technique, because it has no known adverse effects. Sonography is readily available, relatively cheap, and well tolerated by patients.

Most importantly, the technique does not involve use of ionising radiation like computed tomography (CT) (9). Despite the advantages in sonographic measurements of ONSD, there is paucity of local data among the healthy population in African continent. This made us to undertake the current study that aimed at determining the normal ONSD through orbital sonography and correlating the measured ONSD with age and sex as well as the body height and weight of the study subjects.

## Materials and Methods

This prospective study was carried out between March 2012 and February 2013 at Aminu Kano Teaching Hospital (AKTH), a tertiary health facility located in Kano, Northwestern Nigeria. The study included 400 healthy volunteers of Nigerian nationality using convenient sampling method.

### Sample size determination

Sample size was determined using Fisher's statistical formula:

$$n = \frac{Z^2pq}{d^2}$$

Where:

- n = minimum sample size
- Z = percentage of the standard normal distribution curve, defining 95% confidence interval (CI) of 1.96
- p = prevalence rate from a previous study

Assuming half of the population having normal ONSD, we took p = 50 % (0.5)

- q = complimentary probability, which equals to 1-p
- d = margin of error, which is 5 %, equivalent to 0.05

Therefore, the minimum sample size would be:

$$n = (1.96)^2 \times 0.5 \times 0.5 \\ (0.05)^2 = 384.16$$

The number was taken as a round figure of 400 and this was used as the sample size for our study.

The apparently healthy volunteers without any visual or other symptoms related to central nervous system were included for this study, and written consent was obtained from each participant. The volunteers, mostly consisted of university students, individuals who come for routine pre-employment (or school admission) medical check up, hospital staff, and residents of hospital staff quarters. Individuals with ophthalmic disease, head or ocular trauma, intra cranial tumours, patients with suspected raised ICP, h unilateral or bilateral enucleation, non-Nigerians, and those below 16 years of age were excluded from the study.

### Ethical considerations

The study was approved by the ethics and research committee of AKTH. In addition, informed written consents were also obtained from the study participants; they were informed regarding the nature of the ultrasound ocular examination and their right to refuse to participate at any stage of the study. None of the participants withdrew from the study. However, two of the participants were found to have partial retinal detachment during the panoramic examination and were excluded and replaced by two other individuals with sonographically healthy eyes.

### Technique of optic nerve sonography

After documenting the age and gender of the participants on a structured data check list, history of eye or neurologic disease was asked to exclude individuals that did not qualify for inclusion. The height (in meter) and weight (in kg) of each participant was obtained using bathroom weight scale and stadiometer, respectively. Each participant was instructed to lie in supine position on the ultrasound examination couch and was requested to shut the eyelids while maintaining gaze at the ceiling; coupling and gel was applied over the lid. A 7.5 MHz linear transducer of the Mindry Digital Ultrasound Imaging System (Model DP-8800Plus; Shenzhen Mindray Biomed electronics, China) was used. The transducer was placed over the closed eyelid. The scanning was done in the transverse, longitudinal and cranio-caudal planes of each eye. Placement of the transducer was adjusted to bring the best angle for displaying the exit of the optic nerve from the globe (4,6).

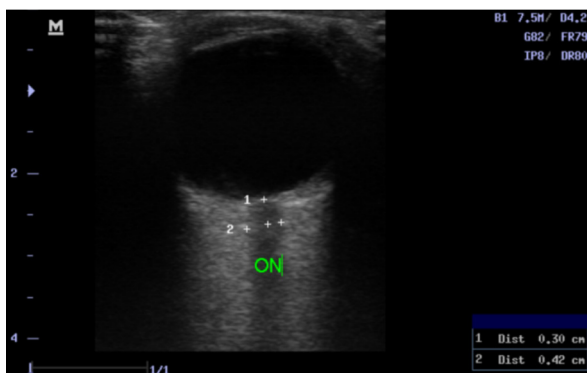
For proper alignment of the optic nerve directly opposite the probe, eye structures were imaged. This was achieved by ensuring that the posterior aspect of the lens was visible in the scan. Attention was also paid to avoid compressing the

eye with the transducer.

The widest visible retrobulbar ONSD was measured at a point 3 mm posterior to the posterior scleral surface of the globe using an in-built electronic caliper to the nearest millimetre; with an angle perpendicular to the eye ball (Figure 1). The measurements were triplicated, and the average was entered as the recorded ONSD. All measurements were performed by the same observer to eliminate inter observer variation. Measurements were made bilaterally.

## Results

Among the 400 adults participants, there were 192 (48%) males and 208 (52%) females yielding a ratio of male and female of 9.2:10.0 (Table 1). Their ages ranged from 18–80 years with a mean age of 36.94 years (SD 16.63); the median age was found to be 49 years (range of 18–80 years).



**Figure 1:** A coned view of high resolution sonogram of the globe, showing reference points for measuring the optic nerve (ON) at a point, 3 mm form the posterior sclera surface (between cursors). It shows the value of 4.2 mm.

The range of values was obtained for ONSD (3.36–5.1 mm). The median right ONSD was 4.110 with a range of 3.36–4.86 mm, mean: 4.18 mm (SD 0.49 mm), while the median left ONSD was 4.35 mm with a range of 3.77 mm to 5.10 mm, mean: 4.17 (SD 0.44 mm). Among male participants, the mean right ONSD was 4.18 mm, while that of the left was 4.16 mm. For female participants, the mean right and left ONSD were measured 4.17 mm each. There was no statistically significant variation in ONSD between males and females ( $P = 0.296$  and  $0.745$  for the respective right and left ONSD, respectively). No statistically significant difference was observed between the right and left ONSD values ( $P = 0.12$ ). Table 2 presents a comparison between the height of the participants and ONSD; we obtained a weak correlation between these variables. On the other hand, we obtained a positive Pearson’s correlation co-efficient ( $r$ ) between the right ONSD and the weight of the participants ( $r = 0.136$ ;  $P = 0.006$ );

**Table 1:** Age-sex distribution of the study subjects

Age Groups (years)	Male	Female	Total (%)
15–24	52	100	152 (38)
25–34	36	23	59 (14.25)
35–44	35	28	63 (15.75)
45–54	28	19	47 (11.75)
44–64	20	17	37 (9.25)
65–74	20	14	34 (8.5)
≥ 75	1	7	8 (2)
Total	192	208	400 (100)

**Table 2:** Correlation between the measured mean ONSD and the body weight and heights of the study subjects

		Right ONSD	Left ONSD
Weight	Pearson Correlation	0.136**	0.219**
	Sig. (2-tailed)	0.006	0.000
Height	Pearson Correlation	-0.055	0.047
	Sig. (2-tailed)	0.273	0.351

\*\* Correlation is significant at the 0.01 level (2-tailed).  
ONSD = optic nerve sheath diameter.

however, when right ONSD was compared with respect to the participants' height, we found a negative correlation ( $r = -0.55$ ;  $P = 0.273$ ). The same pattern was also noted for the left ONSD; a positive Pearson's correlation coefficient between the left ONSD and the weight of the participant ( $r = 0.219$ ;  $P = 0.009$ ), while measured negative correlation when compared to height ( $r = -0.47$ ;  $P = 0.351$ ).

Table 3 summarises the mean age and measured ONSD value of the participants based on their gender and age. The highest mean values of measured ONSD were observed in the male age group of > 75 years, measuring 4.18 mm and 4.22 mm on the right and left sides, respectively. The lowest mean values were recorded in females, aged 35–44 years, measuring 4.15 mm and 4.13 mm ONSD on the right and left sides, respectively. No statistically significant correlation was found between ONSD and age. We obtained the Pearson's correlation coefficient between age and right and left ONSD as 0.13 and  $-0.21$ , respectively. Furthermore, we also found their respective coefficient of determination ( $r^2$ ) as 0.0961 and 0.0441 for the right and left ONSD, respectively, with respect to age; thus, suggesting only 9.61 % and 4.41 % of respective right and left ONSD variation could be attributed to the age of the participants.

## Discussion

Individuals from different ethnic groups in different countries and continents vary in characteristics, such as skin colour, facial structure, height, etc. Thus, we thought it is important to measure ONSD for comparing the findings obtained from other parts of the world to resolve regional, racial and individual differences, if they exist. In this context, the sonographic reference value is, therefore, beneficial as it provides the basis for monitoring patients with raised ICP.

Intracranial hypertension implies profoundly disturbed intracranial physiology (11). An increase in the volume of one of the components contained within the intracranial space can only occur at the expense of the other components (12). As the volume of oedema in the brain (or an expanding mass lesion) increases, initially, the CSF volume decreases and then, the blood volume decreases. The continued expansion of intracranial volume, after the exhaustion of these compensatory mechanisms, causes a rapid increase in ICP and herniation of the brain (13).

Although there is no consensus as the cut off for an abnormal ONSD indicating for a raised ICP, elevated ICP could be found in critically ill patients and lead to severe brain damage or a devastating neurological outcome if left untreated (5,10–12,15). Furthermore, it has been clearly demonstrated that increased intracranial pressure that is refractory to initial medical measures is a poor prognostic sign (16). Intracranial pressure (ICP) measurement is an extremely important part of the neurosurgical armamentarium (12,13,17,18). The raised ICP is not only the commonest cause of death in neurosurgical patients, it is extremely common in patients suffering from head injury (11,19). An increase in ICP may, therefore, impede cerebral blood flow (CBF) and cause ischaemia (13,18). Raised ICP is an important secondary insult in brain-injured patients and a predictor of poor outcome after traumatic brain injury. It is used as a target in many treatment algorithms (18).

One reason for monitoring in neurological intensive care is to identify subclinical causes of secondary brain injury and to allow prompt treatment (20). Many studies have shown the benefits of ICP monitoring in avoiding surgery when the initial CT scan was normal (17). The effective treatment of raised ICP has been shown to decrease mortality (19). In order to effectively utilise the value of transorbital sonographic measurement of ONSD in the setting of raised ICP, normal reference value was required as demonstrated by our study. Majority of the participants in the current study are young adults with about 68% of them younger than 45 years (Table 1); thus, reflecting the usual age distribution pattern of Nigeria and other developing nations. Nigeria has a predominantly younger population (21). Moreover, the female participants in the age group of 15 to 24 years constitute about 25% of the entire study population (Table 1).

In their study of measuring ONSD among 32 healthy subjects, Garcia et al. (22) found the normal range of ONSD between 3.9–5.9 mm with mean of 4.8 mm; values higher than 4.18 mm correspond to the right optical nerves, while 4.17 mm to the left optic nerves. The ONSD range found in our study (4.01 mm to 4.38 mm) was not as wide as the range obtained by Garcia et al. (22). This could partly be due to the differences in study design and imaging facilities; because Garcia et al. (22) used a smaller sample size and three-dimensional (3D) ultrasound system, while we carried out this study with a larger sample size consisting of 400 odd participants and used two-

dimensional (2D) grey-scale ultrasound system, which might be the reason for different results. Nevertheless, the measured ONSD in the present study is still less than 5 mm, a critical value that is usually considered abnormal, especially if bilateral, it may suggest raised ICP (23).

In a different set up, Lagrèze et al. (7) used ultrafast magnetic resonance sequences to measure ONSD and found a decrease in optic nerve diameters from 5.72 mm to 3.98 mm, respectively, at 5 mm and 10 mm behind the eye. However, it is difficult to compare their findings with those in our study because of differences in reference points while measuring the ONSD (our study measured optic nerve at 3 mm behind the sclera) and in the imaging modalities used.

Chan and Mok (5) measured ONSD in 100 Hong Kong Chinese individuals to establish normal reference values of ONSD. The authors found the mean right eye ONSD as 4.04 mm, while that of the left eye ONSD as 4.05 mm. The values found by Chan and Mok (5) are little lower than the numbers we obtained; the corresponding numbers in the present study are 4.18 mm and 4.17 mm, respectively. However, in agreement with their findings (5), we also found no statistically significant difference in ONSD between males and females as well as between right and left eyes.

A study involving 102 children, Ballantyne et al. (24) found the ONSD range between 2.1–4.3 mm; a range wider than what was found in the current study. This variation may arise from the differences in the characteristics of the study subjects. Nevertheless, in agreement with our study, Ballantyne et al. (24) also found no statistically significant gender difference in ONSD between right and left sides. In an Iranian case control study conducted by Malayeri et al. (25) on normal children and those with raised ICP, no statistically significant difference was found between right and left ONSD in both the case and the control groups.

Furthermore, we examined the correlation between age and ONSD; however it failed to show any statistically significant correlation between the two variables. The co-efficient of determination ( $r^2$ ) are 0.0961 and 0.0441, respectively, for the right and left ONSD with respect to age. This suggests that only 9.61% and 4.41% of respective right and left ONSD variation could be attributed to the age of the participants. This corroborates the findings of Chan and Mok (5) discussed above. Similar results were also obtained by Garcia et al. (22) on 32 healthy adults.

However, the paediatric population in the study conducted by Ballantyne et al. (24) found a significant correlation between increasing age and increasing ONSD, with the greatest increase occurring in the first two months of life. Another case control study on normal children and those with features of raised ICP also found a significant correlation between age and ONSD in healthy children (25); a significant increase in ONSD with increasing age in children was observed, especially in the first four years of life. However, the present study involving adult population did not find any statistically significant variation between the age and ONSD.

## Conclusions

In the present study, the normal reference values obtained for ONSD measurements can serve as diagnostic aid in appropriate clinical settings. Our results showed no significant correlation of ONSD with side (right and left), age and sex, thus, allowing for local use of the uniform reference values for both sexes as well as right and left optic nerves in adults.

## Acknowledgement

I wish to thankfully appreciate the wonderful support and useful advises of the members of radiology department in the conduct of this study and Bayero University Kano for supporting me to present this work at the World Congress of Ultrasound in medicine and biology.

## Funds

None.

## Conflict of Interest

None.

## Correspondence

Dr Anas Ismail  
MBBS (Bayero University), FMCR (NPMC, Nigeria)  
Department of Radiology  
Bayero University/Aminu Kano Teaching Hospital  
PMB, 3452, Kano  
Nigeria  
Tel.: +234-8039 275 786  
Fax: +064-665 904  
Email: ibnmalikanas@yahoo.co.uk  
a.ismail@buk.edu.ng

## References

1. Ryan S, Nicholas MM, Eustace S. *Anatomy for Diagnostic Imaging*. 2nd ed. Philadelphia (US): Elsevier Limited; 2004.
2. Ellis H. The cranial nerves. In: Ellis H, editor. *Clinical Anatomy*. 11th ed. Oxford (UK) s Ltd: Blackwell Publication; 2002. p. 365–366.
3. Hansen HC, Helmke K. Validation of the optic nerve sheath response to changing cerebrospinal fluid pressure: ultrasound findings during intrathecal infusion tests. *J Neurosurg*. 1997;**87**(1):34–40.
4. Merceron S, Geeraerts T. Ocular sonography for the detection of raised intracranial pressure. *Expert Rev Ophthalmol*. 2008;**5**(5):497–500.
5. Chan PYN, Mok KL. Transorbital sonographic evaluation of optic nerve sheath diameter in normal Hong Kong Chinese adults. *Hong Kong J Emerg Med*. 2008;**15**(4):197–205.
6. Newman WD, Hollman AS, Dutton GN, Carachi R. Measurement of optic nerve sheath diameter by ultrasound: a means of detecting acute raised intracranial pressure in hydrocephalus. *Br J Ophthalmol*. 2002;**86**(4):1109–1113.
7. Lagrèze WA, Lazzaro A, Weigel M, Hansen HC, Hennig J, Bley TA. Morphometry of the Retrobulbar Human Optic Nerve: Comparison between Conventional Sonography and Ultrafast Magnetic Resonance Sequences. *Invest Ophth Vis Sci*. 2007;**48**(6):1913–1917.
8. Ballantyne SA, Neill GO, Hamilton R, Hollman AS. Observer variation in the sonographic measurement of optic nerve sheath diameter in normal adults. *Eur J Ultrasound*. 2002;**15**(3):145–149. doi: 10.1016/S0929-8266(02)00036-8.
9. Bedi DG, Gombos DS, Chaan S, Singh S. Sonography of the Eye. Pictorial Essay. *Am J Radiol*. 2006;**187**(4):1061–1072.
10. Soldatos T, Karakitsos D, Chatzimichail K, Papatheanasiou M, Gouliamos A, Karabinis A. Optic nerve sonography in the diagnostic evaluation of adult brain injury. *Crit Care*. 2008;**12**(3):67. doi: 10.1186/cc6897.
11. Bershad EM, Humphreis WE, Suarez JI. Intracranial Hypertension. *Semin Neurol*. 2008;**28**(5):690–702. doi: 10.1055/s-0028-1105968.
12. Dorobăț GH. Controlling the increased intracranial pressure – a neurointensivist’s point of view. *Romanian Neurosurgery*. 2010;**18**(17):313–319.
13. Ahmad I, Wahab S, Chana RS, Khan AS, Wahab S. Role of Transcranial Doppler and Pressure Provocation in Evaluation of Cerebral Compliance in Children with Hydrocephalus. *HK J Paediatr*. 2008;**13**:110–115.
14. Robert DL. Increased Intracranial Pressure. *Clin Ped Emerg Med*. 2008;**9**(10):83–87.
15. Manno E, Motevallian M, Mfochivè A Navarra M. Ultrasonography Of The Optic Nerve Sheath Suggested Elevated Intracranial Pressure In Epilepsy: Case Report. *Internet J Anesth*. 2010;**26**(1):1.
16. Li LMB, Timofeev I, Czosnyka M, Hutchinson PJA. The Surgical Approach to the Management of Increased Intracranial Pressure after Traumatic Brain Injury. *Anesth Analg*. 2010;**111**(3):736–748.
17. Ailawadhi P, Agrawal D, Sharma BS. Delayed rise in intracranial pressure in patients with head injury. *Indian J Neurotrauma*. 2010;**7**(1):37–40. doi: 10.1016/S0973-0508(10)80009-7.
18. Steiner LA, Andrews PJD. Expand and Monitoring the injured brain: ICP and CBF. *Br J Anaesth*. 2006;**97**(1):26–38. doi: 10.1093/bja/ael110.
19. Baral B, Agrawal A, Cincu R. Intracranial pressure monitoring: Concepts in evaluation and measurement. *Pak J Med Sci*. 2007;**23**(5):798–804.
20. McNamara B, Ray J, Menon D Boniface S . Raised intracranial pressure and seizures in the neurological intensive care unit. *Br J Anaesth*. 2003;**90**(1):39–42. doi: 10.1093/bja/aeq008.
21. United Nations population division. World population prospects: population data base. 2008. <http://esa.un.org/unpp>. Last updated on 11-Mar-2009.
22. Garcia JPS, Garcia PT, Rosen RB, Finger PT. A 3-dimensional ultrasound C-scan imaging technique for optic nerve measurements. *Ophthalmology*. 2004;**111**(6):1238–1243.
23. James WT, Michael B, Arthur C, Nadine L. A Rapid Noninvasive Method of Detecting Elevated Intracranial Pressure Using Bedside Ocular Ultrasound: Application to 3 Cases of Head Trauma in the Pediatric Emergency Department. *Pediatric Emerg Care*. 2005;**21**(2):94–98.
24. Ballantyne J, Hollman AS, Hamilton R, Bradnam MS, Carachic MS, Young DG, Dutton GN. Transorbital optic nerve sheath ultrasonography in normal children. *Clin Radiol*. 1999;**54** (11):740–742.
25. Malayeri AA, Bavarian S, Mehdizadeh M. Sonographic Evaluation of Optic Nerve Diameter in Children with Raised Intracranial Pressure. *J Ultrasound Med*. 2005;**24**(2):143–147.