

Dalia F. ABDULWAHAB, Hamizah ISMAIL, Zalina NUSEE

Submitted: 29 Oct 2013

Accepted: 17 Feb 2014

Department of Obstetrics & Gynaecology, Kulliyah of Medicine,
International Islamic University Malaysia, Jalan Hospital Campus,
25150 Kuantan, Pahang, Malaysia

Abstract

Uterine rupture is a rare life-threatening complication. It mainly occurs in the third trimester of pregnancy and is rarely seen during the first or second trimesters. Our centre experienced three important cases of uterine rupture. First case: spontaneous uterine rupture at 14 weeks of pregnancy, which was diagnosed at autopsy. It was misled by the ultrasound finding of an intrauterine pregnancy, and searching for other non-gynaecological causes delayed the urgent obstetric surgical management. Second case: ruptured uterus at 24 weeks following medical termination due to foetal anomaly. It was diagnosed only at laparotomy indicated for failed medical termination and chorioamnionitis. Third case: uterine rupture at 21 weeks of pregnancy in a patient with gastroenterology symptoms. In these reports, we have discussed the various risk factors, presentations, course of events and difficulties in diagnosing uterine rupture. The study concludes that the clinical presentation of uterine ruptures varies. It occurs regardless of gestational age. Ultrasound findings of intrauterine pregnancy with free fluid do not exclude uterine rupture or ectopic pregnancy. Searching for non-gynaecological causes in such clinical presentations might delay crucial surgical intervention, which leads to unnecessary morbidity, mortality or loss of obstetrics function.

Keywords: uterine rupture, placenta increta, acute abdomen

Introduction

Uterine rupture is a serious obstetric complication that occurs mainly in the third trimester of pregnancy or during labour, especially in previously scarred uterus. It is rare in unscarred uterus. Advanced maternal age, grand multiparous, placenta increta, macrosomia, shoulder dystocia, and medical termination of pregnancy are some contributing factors to uterine rupture. The overall incidence of uterine rupture in unscarred and scarred uteruses is 0.7 and 5.1 per 10 000 deliveries, respectively (1).

Uterine rupture in the first or second trimester of pregnancy is extremely rare, and may vary in presentation and course of events, which make the clinical diagnosis challenging. These may be masked by changes in physiology and anatomy during pregnancy. The lack of high index of suspicion diverts attention to search for other non-gynaecological problems (2).

Our aim is to create awareness by illustrating how the delay in diagnoses of three interesting cases of uterine rupture lead to not only loss of fertility, but also loss of life.

Case 1

A 38 year-old woman, gravida six, para three (G6P3), pregnant at 14 weeks presented with a sudden onset of epigastric pain that radiated to her back following sexual intercourse. Her first pregnancy with her first husband was a caesarean delivery for term breech presentation followed by two successful vaginal deliveries. During this second marriage, she had two first trimester miscarriages where dilatation and curettage (D&C) was performed.

She was brought to the nearest health centre at midnight because of the pain. Her blood pressure (BP) was 110/60 mmHg, pulse rate (PR) was 100/min, body temperature (T) was 37 °C, respiratory rate (RR) was 26/min, and SpO₂ was 100%. She was provided intravenous ranitidine and fluids, but her symptoms remained unchanged. Therefore, an ambulance transfer to tertiary hospital was arranged.

On arrival to the hospital, she was gasping and pale. She had Glasgow coma scale of 5/15, BP of 49/20 mmHg, pulse rate of 138/min, T = 35 °C and both pupils were 4 mm dilated. Unfortunately,

she went into cardio respiratory arrest despite immediate intubation. A quick ultrasound by the casualty doctor revealed intrauterine pregnancy, no free fluid in the abdomen and no evidence of aortic aneurysm. She was referred and managed by medical, surgical and obstetrics team.

Her abdominal girth was noted to be increased. Abdominal and pelvic ultrasound by obstetrician revealed an intrauterine pregnancy of a nonviable foetus with free fluid in the pelvis and abdomen. Peritoneal tap confirmed haemoperitoneum. Her blood results showed that haemoglobin (Hb) dropped from 8.2–2.5 gm%, and platelets from 385 to $81 \times 10^3/\text{mm}^3$. Unfortunately, she went into second asystole and succumbed.

Autopsy revealed a haemoperitoneum of 2000 mls of fresh blood mixed with clots. The stomach, liver, spleen, kidneys, and major vessels were normal. There was a rupture of the uterine fundus measuring 8 x 5 cm, exposing the amniotic membrane with foetus (225 gm) and placenta that were still inside the uterus (Figure 1). Part of the placenta was seen at the ruptured area attached to the uterus fundus (Figure 1). The previous caesarean scar was intact. Blood clots were seen surrounding the uterus. Histopathology confirmed ruptured uterus with placenta increta (Figure 2).

Case 2

A 36-year-old grand multiparous woman (G9P8) with a non-scarred uterus at 24 weeks period of amenorrhoea was admitted for medical termination of pregnancy due to prenatal diagnosis of large encephalocele. She was induced with a daily dose of 1 mg gemeprost (cervagem) as per hospital induction protocol. She started to have contractions, pain, fever, and minimal vaginal bleeding after two doses of gemeprost. The cervix effaced to 1 cm long and cervical os dilated to 3 cm; the membrane was intact.

As her uterine contractions ceased, third gemeprost was then inserted. On the fourth day, she experienced palpitation and right iliac fossa pain. Examination revealed that she had a temperature of 38 °C, SpO₂ of 99%, was normotensive and exhibited tenderness over suprapubic region. The cervical findings remained the same. Her Hb dropped from 10.4 to 8.9 g/dL, and total white blood cell (TWC) increased from 13.45 to $21.17 \times 10^9/\text{L}$. She was then treated for chorioamnionitis in which intravenous antibiotics and septic work out was carried out.

The labour was further augmented with intravenous oxytocin as per protocol. She developed giddiness, nausea, vomiting, and intermittent abdominal pain. She was tachycardic PR of 96/min but with normal blood pressure. Finally, she was brought to the operating room on suspicion of uterine rupture after 8 hours of oxytocin infusion with no cervical dilatation.

Intra-operatively, there was a uterine rupture extending from uterine isthmus to the body of the right side of the uterus. The foetus with encephalocele was in the abdominal cavity with placenta loosely attached to the mesentery of the small intestine. She had undergone total abdominal hysterectomy and bled 2700 mL. Post-operative was uneventful, and she fully recovered.

Case 3

A 34-year-old lady, G4P3, (first pregnancy with her third husband) at 21 week period of gestation, presented to the local health clinic with lower abdominal pain and constipation. She was diagnosed with acute gastritis and was prescribed lactulose. The next day she developed severe acute abdominal pain associated with diarrhea and vomiting after consuming the whole bottle of lactulose (120 mL). However, there was no vaginal bleeding or syncopal attack. She was then transferred to tertiary hospital.

She was lethargic and dehydrated. Her BP was 90/60 mmHg and PR was 100 bpm. The abdomen was mildly distended, soft with mild tenderness over the epigastric region and clinical fundal height measured 20 cm. Trans-abdominal scan by the first line doctor showed viable foetus with no free fluid in the pouch of Douglas. Her Hb was 6.5 g/dL, platelets count was normal and white blood cell (WBC) increased to $28 \times 10^9/\text{L}$. She was treated for acute gastroenteritis with adverse effects of lactulose. Investigation for the cause of anaemia was carried out prior to blood transfusion.

She deteriorated two hours later where she became breathless, hypotensive, and tachycardic. The abdomen was grossly distended, extremely tender and guarding suggestive of peritonitis. Ultrasound examination showed viable foetus with free fluid at the pouch of Douglas. Left adnexal mass measured 7.5×5 cm. However, the uterine outline was not clearly visualised. She was taken for laparotomy with an impression of extrauterine pregnancy with acute intra-abdominal haemorrhage.

Laparotomy findings revealed 3 L of haemoperitoneum, adhesion between omentum,

and uterus, and perihepatic adhesions. The uterus was irregularly enlarged - bulging and thin over left fundus and ruptured at the posterior wall measuring 5 × 5 cm. Part of the placenta expelled out through the ruptured uterus with the foetus still inside (Figure 3). A diagnosis of ruptured corneal pregnancy was made. Total abdominal hysterectomy was carried out. She had massive blood loss of 5 L and received 10 units of blood transfusion. Post-operatively, she recovered well. The histopathology confirmed left tubal interstitium pregnancy.

Discussion

Uterine rupture is extremely rare in first and second trimester of pregnancy and is usually diagnosed intra-operatively (2,3). This study aimed to highlight various presentations and course of events that subsequently result in diagnostic and decision-making difficulties.

In the first case, misleading factors include severe epigastric pain following sexual intercourse and intrauterine pregnancy. These delayed obstetrics referral, where the patient was referred to medical and surgical team for causes of acute abdomen.

The autopsy showed that the uterus ruptured at the fundal height and not at the previous caesarean scar. The autopsy revealed the patient's history of twice uterine evacuation. Uterine rupture at this early pregnancy stage was probably a complication of the two previous curettage that damaged the endometrium. This emphasises the importance of medical history, and that the patient and spouse should be informed and keep records of previous surgeries to have a high index of suspicion.

Ultrasound diagnosis of intrauterine pregnancy together with fluid collection does not mean that the uterus is intact, or there is no ectopic pregnancy. Search for other non-gynaecological or obstetrics causes (such as perforated gastric ulcer, ruptured abdominal aortic aneurysm, etc.) would just delay urgent management that can affect the outcome.

Unlike rupture in the lower uterine segment in the third trimester or during delivery, the common site of rupture in the first trimester is the fundal region (3,4). Recent publications reveal that morbidly adherent placenta causes early uterine rupture (5,6). The histopathology findings of placenta increta emphasised that morbidly adherent placenta should be suspected in previous uterine surgeries. Uterine rupture with placenta increta can be more dangerous than

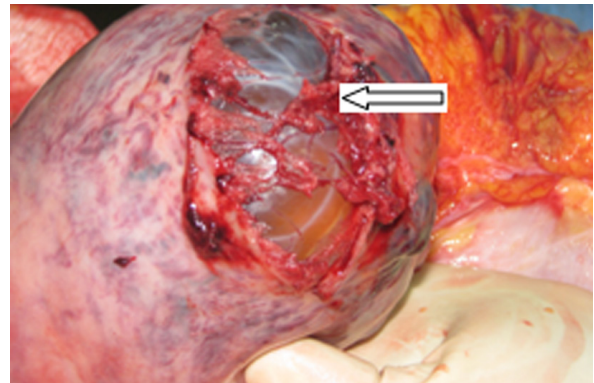


Figure 1: Uterine ruptured at fundus exposing placenta tissue with intact amniotic sac and non-viable fetus in situ.

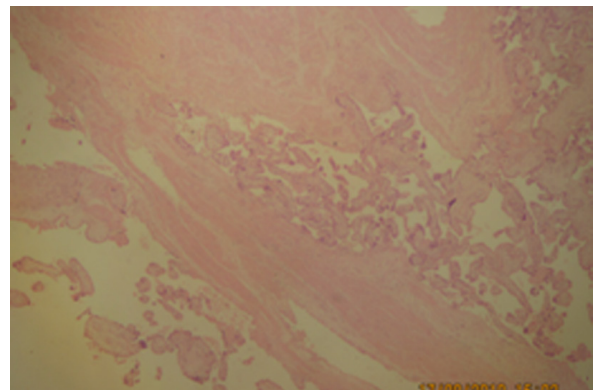


Figure 2: Histopathology invasion of the chorionic villi into myometrium.

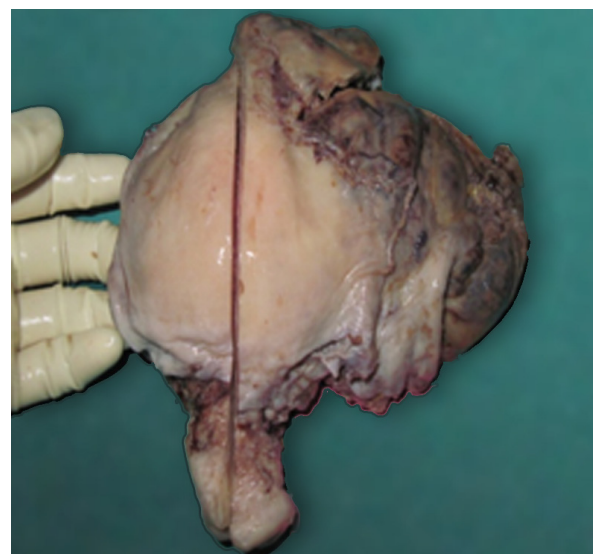

Figure 3: Uterine ruptured at fundus exposing placenta tissue with intact amniotic sac and nonviable fetus in situ.

that caused by just scarred uterus because of more vascularisation at the placental site as seen in the first case when the patient deteriorated very fast (6,7).

For the second case, the risk factor is grand multipara and medical induction. One should be vigilant with the use of gemeprost in grand multipara. Although gemeprost is largely used and considered safe for mid-trimester abortion, there are reported cases of uterine rupture following their administration (8). A continuous abdominal pain, cessation of uterine contraction, and a non-progressing cervical dilatation should give rise to a clinical suspicion of rupture. However, due to the presence of high grade fever, normal BP with mild rise in PR, and significant rise in WBC, one tends to take these as symptoms for chorioamnionitis rather than for uterine rupture.

In the third case, the risk factor was an ectopic pregnancy and infections in a multiple sexual partner lady with evidence of pelvic inflammatory disease. The case was misled when she was presented with abdominal pain and constipation, and later, with diarrhoea from the side effects of the treatment. In such cases, careful pelvic examination and pelvic ultrasound might help to identify the exact location of the pregnancy. However, it is not easy to diagnose cornual pregnancy. Only 40% cases of first and second trimester uterine rupture related to cornual pregnancy were diagnosed by ultrasound, 80% with severe abdominal pain and 60 % with a sign of shock (2).

In this report, we strongly address that pregnancy and related complications should be always considered first when assessing a pregnant lady with acute abdominal pain. This should be considered especially for haemodynamically stable and unstable patients associated with intraperitoneal free fluid, even in the case of intrauterine pregnancy.

Clinicians, especially first liners, should be aware of anatomical changes in pregnancy as the uterus is enlarged and becomes an abdominal organ. In evaluating a pregnant lady, mild abdominal pain or discomfort may be acceptable, but severe sudden pain associated with vomiting, sign of peritoneal irritation, and possible obstetric etiology should be considered seriously and should be the first to be correlated (9).

The managing clinician should also be aware of the physiologic pregnancy adaptations, where blood and erythrocyte volume increase by 50% and 30%, respectively. A pregnant woman is physiologically prepared to lose blood up

to 2 L without any detectable haemodynamic changes. When blood loss approaches 2.5 L, she can deteriorate dramatically (10). Therefore, prompt action and intervention is crucial in case of hypovolemia.

Conclusion

We have emphasised on the importance of keeping medical history, clinical examination and record keeping. Ultrasound findings of intraperitoneal fluid collection with an intrauterine pregnancy do not exclude uterine rupture or ectopic pregnancy. Uterine rupture should be first ruled out in all pregnant women presented with acute abdominal pain regardless of their gestational age. Search for non-gynaecological causes in such clinical presentations can delay crucial obstetric surgical intervention that can lead to loss of obstetrics function, morbidity and mortality.

Acknowledgement

None.

Conflict of Interest

None.

Funds

None.

Authors' Contributions

Conception and design, analysis and interpretation of the data, drafting of the article: DFA

Critical revision of the article for the important intellectual content: HI

Final approval of the article: DFA, HI, ZN

Provision of study materials or patient: ZN

Correspondence

Dr Dalia F. Abdulwahab
MBChB (Al Mustansiriya University), CABOG (The Arab Board of Medical Specializations in Obstetrics & Gynaecology), FIBMS (The Iraqi Board of Medical Specializations in Obstetrics & Gynaecology)
Department of Obstetric & Gynaecology
International Islamic University Malaysia
Jalan Hospital Campus
25150 Kuantan, Pahang
Fax: +609-516 3764
Tel: +6016-379 6387
Email: daliafrk@yahoo.com

References

1. Smith JF, Wax JR. Rupture of the unscarred uterus [Internet]. [Place of publication unknown]: UpToDate; 2013 [cited 2013 Aug 22]. Available from: www.uptodate.com.
2. Arbab F, Boulieu D, Bied V, Payan F, Lornage J, Guerin JF. Uterine rupture in first or second trimester of pregnancy after in-vitro fertilization and embryo transfer. *Hum Reprod*. 1996;**11(5)**:1120–1122.
3. Park YJ, Ryu KY, Lee JI, Park M. Spontaneous Uterine Rupture in the First Trimester: A case Report. *J Korean Med Sci*. 2005;**20(6)**:1079–1081.
4. Schrinky DC, Benson RC. Rupture of the pregnant uterus: a review. *Obstet Gynecol Surv*. 1978;**33(4)**:217–232.
5. Dabulis SA, McGuirk TD. An unusual case of hemoperitoneum: uterine rupture at 9 weeks gestational age. *J Emerg Med*. 2007;**33(3)**:285–287. doi: 10.1016/j.jemermed.2007.01.009.
6. Jang DG, Lee GSR, Yoon JH, Lee SJ. Placenta-Induced Uterine Rupture Diagnosed By Laparoscopy in the first Trimester. *Int J Med Sci*. 2011;**8(5)**:424–427. doi: 10.7150/ijms.8.424.
7. Miller DA, Chollet JA, Goodwin TM. Clinical risk factors for placenta previa-placenta accrete. *Am J Obstet Gynecol*. 1997;**177(1)**:210–214. doi: 10.1016/S0002-9378(97)70463-0.
8. Pappalardo EM, La Greca M, Rapisarda G, Consoli D. Uterine rupture after prostaglandin analogues to induce midtrimester abortion. *J Prenat Med*. 2010;**4(1)**:9–11.
9. Kilpatrick CC, Orejuela FJ. Approach to abdominal pain and the acute abdomen in pregnant and postpartum women [Internet]. United States (US); Wolters Kluwer Health; 2013 [cited 2013 Aug 22]. Available from: www.uptodate.com.
10. Hill CC, Pickinpaugh J. Trauma and Surgical Emergencies in the Obstetric Patient. *Surg Clin N Am*. 2008;**88(2)**:421–440. doi: 10.1016/j.suc.2007.12.006.