

Daphne Dewi STEPHEN, Sze Li SLOW

Submitted: 27 May 2011

Accepted: 29 Jun 2011

*Department of Surgery, Sarawak General Hospital, Jalan Hospital, 93586 Kuching, Sarawak, Malaysia*

## Abstract

Acute lower gastrointestinal haemorrhage secondary to small bowel ascariasis is extremely rare. A high level of suspicion should be maintained when dealing with acute gastrointestinal haemorrhage in migrants and travellers. Small bowel examination is warranted when carefully repeated upper and lower endoscopies have failed to elicit the source of bleeding. Appropriate test selection is determined by the availability of local expertise. We present a case of acute lower gastrointestinal haemorrhage secondary to jejunal ascariasis and a literature search on lower gastrointestinal haemorrhage associated with jejunal infestation with *Ascaris*.

**Keywords:** *ascariasis, aetiology, complications, diagnosis, gastrointestinal haemorrhage, jejunal diseases, melaena, parasitology*

## Introduction

Lower gastrointestinal haemorrhage is defined as intraluminal blood loss from a source distal to the ligament of Treitz. Typical causes include large bowel diverticular disease, anorectal pathologies, benign or malignant neoplasias, inflammatory bowel disease, vascular malformations, and angiodysplasias. Small bowel haemorrhages account for 5% of lower gastrointestinal haemorrhages and often are the source of obscure gastrointestinal haemorrhage when the diagnosis cannot be established by conventional upper and lower endoscopy. We present a case of acute lower gastrointestinal haemorrhage secondary to jejunal ascariasis and a literature search on lower gastrointestinal haemorrhage associated with jejunal infestation with *Ascaris*.

## Case Report

A 65-year-old Indonesian woman was referred from a district hospital with a 1-day history of passing a black, tarry stool. She had no abdominal discomfort, no constitutional symptoms and no alteration in appetite or bowel habits. Upon examination, although she was alert and not in distress, her conjunctiva was pale. Her vital signs were stable with no evidence of hypovolaemic shock. An abdominal examination was unremarkable, and a digital rectal examination revealed fresh melaena. Otherwise, her examination was normal.

Laboratory investigations revealed that her haemoglobin level was 4.8 g/dL and that her platelet count was 496 000 U/L. She had no coagulopathy. An emergency upper gastrointestinal endoscopy performed upon admission was normal. She was then admitted, underwent blood transfusion, and was scheduled for colonoscopy the next day. Colonoscopy result showed stale melaena along the entire length of her large bowel, with no identifiable source of bleeding.

During admission, she continued to pass fresh melaena and was transfused a total of 9 units of packed cells because she was persistently anaemic. An emergency computed tomography (CT) angiogram identified active bleeding into the jejunum that originated from one of the branches of the superior mesenteric artery. Interventional embolisation was initiated, but the bleeding stopped during the procedure. The procedure was abandoned as there was no further demonstrable angiographic evidence of active bleeding from either the celiac or the superior mesentery arteries. The following day, she began to bleed again while in the ward, and a decision to perform surgery was made.

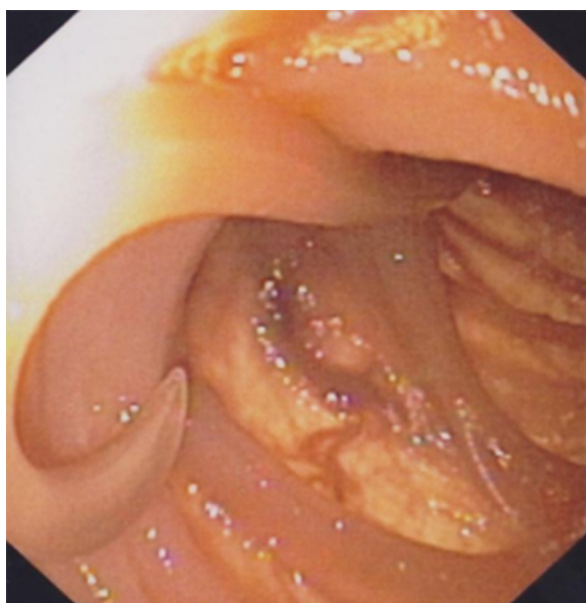
A laparotomy did not show any gross pathology of the stomach, small bowels, or colon. An enterotomy was performed at the jejunum (130 cm from the duodenojejunal [DJ] flexure) and was followed by an on-table enteroscopy. With a soft bowel clamp applied distally to the enterotomy, the endoscope was advanced proximally, which revealed fresh blood

oozing from mucosal erosions of the jejunum approximately 120 cm from the DJ flexure. Further examination proximal to the mucosal erosions revealed a viable adult *Ascaris* over the proximal jejunum (Figure 1). Enteroscopic examination distal to the enterotomy towards the ileocaecal valve showed haematin stains along the entire length of the distal jejunum and ileum. The parasite was removed via a second enterotomy 60 cm from the DJ flexure. A small bowel resection with end-to-end anastomosis was performed for the length of the jejunum that had the bleeding erosions. Histopathological examination of the resected jejunum showed a normal small bowel with lymphoid hyperplasia.

The patient recovered uneventfully with no further episodes of gastrointestinal haemorrhage and was well at discharge with oral albendazole (400 mg). Examination of the parasite confirmed an adult *Ascaris lumbricoides*.

## Discussion

The World Health Organization (1) estimated that more than 1 billion of the world's population is infected with one or more of the soil transmitted helminths, particularly *Ascaris lumbricoides*, *Trichuris trichiura*, and *Necator americanus* or *Ancylostoma duodenale*. These infections, together with schistosomiasis, represent more than 40% of the disease burden caused by all tropical diseases, excluding malaria (2).



**Figure 1:** On-table enteroscopic finding of an *Ascaris*.

Ascariasis is a common infection in children of tropical countries due to poor sanitation. It is, however, rare in adults. Infection is acquired via faecal-oral transmission through ingestion of food, water, or soil contaminated with embryonated eggs (3). Upon ingestion, the eggs hatch in the stomach and duodenum and release the larvae into the duodenum. The larvae then penetrate the intestinal wall to enter the portal circulation. From there, the larvae follow the venous and the lymphatic systems to enter the right side of the heart, the pulmonary circulation and, finally, the pulmonary capillaries. In the lung, the larvae penetrate through the capillaries into the alveoli and travel up the trachea into the pharynx, where they return to the small intestine through the swallowing of bronchial secretions. The larvae mature into adult roundworms within the lumen of the small intestine, especially the jejunum, and reach a size of 15–35 cm in approximately 2 months. Adult worms can survive in the intestine for 6–18 months. After mating, the females begin egg production 2–3 months after the initial infection. The adult female ascarids are somewhat larger than the males, measuring 22–35 cm in length and 3–6 mm in width, whereas the males are 15–31 cm in length and 2–4 mm in width. The adult worms are fusiform and cylindrical in shape and white or creamy-pink in colour. The anterior end of the ascarid is blunt, whereas the posterior end is pointed and, in the male, coiled (4).

*Ascaris lumbricoides* can cause a myriad of surgical complications in the abdomen. The most common complication of ascariasis is intestinal obstruction caused by a worm bolus, which may present as an acute or subacute intestinal obstruction or alternatively as intussusceptions, perforation and gangrene of the small bowel (5). Other areas where adult worms could lodge are in the appendix, causing acute appendicitis and appendicular perforation, or in the biliary and pancreatic ducts, causing hepato-pancreatic ascariasis. In addition, acute upper airway obstruction due to roundworms has been documented.

Gastrointestinal bleeding appears to be uncommon with ascariasis. Typically, ascariasis may present with chronic occult bleeding and anaemia, but rarely with acute gastrointestinal bleeding. The clinical disease is largely restricted to individuals with a high worm load. Intestinal mucosal ulceration is thought to be due to the mechanical trauma from the worm's attachment to the intestinal lining and to mucosal chemical irritation caused by the worm's secretions (6).

The first report published in English medical literature on acute massive jejunal bleeding caused by ascariasis was by Sharma et al. (6) in 2000. The authors described the use of push enteroscopy to diagnose the presence of *Ascaris* and reported the presence of multiple rounded or oval erosions, 2–4 mm in size, associated with fresh blood oozing from erosions. Since then, few reports have emerged to describe the presence of *Ascaris lumbricoides* during capsule endoscopic examinations for obscure gastrointestinal haemorrhage (7,8).

As a general rule, melaena occurs when the source of bleeding is proximal to the ligament of Treitz. The time required for blood to be broken down in the intestinal lumen is approximately 14 hours. Therefore, the explanation for why this patient had melaena rather than haematochesia is that the bleeding was slow and the transit time was greater than 14 hours.

In patients with overt obscure gastrointestinal bleeding with negative upper endoscopy and colonoscopy, further investigations of the small bowel should be performed early. Various approaches have been used in the diagnosis and treatment of small bowel bleeding. These include radiographic approaches, such as small-bowel follow-through and enteroclysis; various forms of enteroscopy, such as push, double or single balloon, and spiral; radionuclide red blood cell scans; angiography; capsule endoscopy; and intra-operative enteroscopy. No single technique has emerged as the most efficient way to evaluate small bowel bleeding, and the procedure chosen should be tailored to the clinical scenario, availability, and local expertise (9).

Angiography may be helpful in patients with active bleeding greater than 0.5 mL/minutes in whom highly vascular non-bleeding lesions such as angiodysplasia and neoplasms can be identified (9). In our case, CT angiography was able to localise the site of the haemorrhage and prompted us to plan for embolisation. However, the repeat angiography did not demonstrate any active extravasation into the lumen of the bowel due to the fact that the bleeding may have stopped.

Intra-operative enteroscopy during laparotomy was used as a last resort in our patient as she continued to bleed, requiring blood transfusions. However, this technique has a moderate therapeutic efficacy because it only identifies the site of occult bleeding in up to 40% of undiagnosed cases and allows examination of just 50% to 80% of the small bowel (10). In our case, its diagnostic accuracy was aided by pre-operative CT angiographic localisation.

In summary, acute lower gastrointestinal haemorrhage secondary to ascariasis is extremely rare. A high level of clinical suspicion is required when dealing with acute gastrointestinal haemorrhage in migrants and travellers. In the near future, less invasive forms of investigation, such as capsule and balloon enteroscopy, may be available to identify obscure gastrointestinal bleeding. Otherwise, laparotomy and intra-operative enteroscopy are often used as a last resort to identify the source of bleeding.

## Acknowledgement

We wish to thank the Director General of Health, Malaysia, for the permission to publish this paper.

## Authors' Contributions

Conception and design, provision of patient, critical revision and final approval of the article: SLS  
Collection and assembly of data, drafting of the article: DDS

## Correspondence

Dr Siow Sze Li  
MBBS (Monash), MRCS (Ire), MRCS (Edin),  
MSurg (UM), Diploma in Laparoscopic Surgery  
(France), Fellowship in Advanced Laparoscopic  
and Bariatric Surgery (France)  
Department of Surgery  
Sarawak General Hospital  
Jalan Hospital  
93586 Kuching  
Sarawak, Malaysia  
Tel: +608-227 6428  
Fax: +608-241 9495  
Email: szeli18@yahoo.com

## References

1. World Health Organization. *Deworming for health & development. Report of the third global meeting of the partners for parasite control*. Geneva (CH): World Health Organization. 2005.
2. Al-Mekhlafi MS, Atiya AS, Lim YA, Mahdy AK, Ariffin WA, Abdullah HC, et al. An unceasing problem: Soil-transmitted helminthases in rural Malaysian communities. *Southeast Asian J Trop Med Pub Health*. 2007;**38**(6):998–1007.
3. Gaash B. *Ascaris lumbricoides*. *Indian J Practising Doctor*. 2004;**1**(3):11–12.
4. Palmer PES, Reeder MM. *The imaging of tropical diseases: With epidemiological, pathological and clinical correlation: Volume 1*. 2nd ed. Maryland: Springer; 2001.

5. Refeidi A. Live *Ascaris lumbricoides* in the peritoneal cavity. *Ann Saudi Med.* 2007;**27(2)**:118–121.
6. Sharma BC, Bhasin DK, Bhatti HS, Das G, Singh K. Gastrointestinal bleeding due to worm infestation, with negative upper gastrointestinal endoscopy findings: Impact of enteroscopy. *Endoscopy.* 2000;**32(4)**:314–316.
7. Floro L, Pak G, Sreter L, Tulassay Z. Wireless capsule endoscopy in the diagnosis of helminthiasis. *Gastrointest Endosc.* 2007;**65(7)**:1078–1079.
8. Balachandran P, Prasad VG. Intestinal parasites seen on capsule endoscopy. *Gastrointest Endosc.* 2006;**64(4)**:651.
9. Leighton JA, Goldstein J, Hirota W, Jacobson BC, Johanson JF, Mallery JS, et al. Obscure gastrointestinal bleeding. *Gastrointest Endosc.* 2003;**58(5)**:650–655.
10. Mitchell SH, Schaefer DC, Dubagunta S. A new view of occult and obscure gastrointestinal bleeding. *Am Fam Physician.* 2004;**69(4)**:875–878.